ALBERT EINSTEIN
HOSPITAL ISRAELITA
DIAGNÓSTICO POR IMAGEM

X CONGRESSO INTERNACIONAL DE
UROONCOLOGIA
V SIMPÓSIO MULTIPROFISSIONAL DE URO-ONCOLOGIA
4 a 6 de abril de 2019 | SHERATON WTC | GOLDEN HALL

Ressonância Magnética Multiparamétrica da Próstata

Ronaldo Hueb Baroni

Coordenador Médico do Setor de Ressonância Magnética e
do Grupo de Radiologia Abdominal do Hospital Israelita Albert Einstein

ALBERT EINSTEIN
HOSPITAL ISRAELITA
DIAGNÓSTICO POR IMAGEM

X CONGRESSO INTERNACIONAL DE
UROONCOLOGIA
V SIMPÓSIO MULTIPROFISSIONAL DE URO-ONCOLOGIA
4 a 6 de abril de 2019 | SHERATON WTC | GOLDEN HALL

Não há conflito de interesse

Há muito tempo, na JPR 2005...

Conclusão: RM no Ca prostático

- Melhor método para estadiamento loco-regional, em casos selecionados*
- Utilizar bobina endorretal
- Espectroscopia e **perfusão**:
  - auxiliam no diagnóstico (localização de áreas suspeitas para re-biópsia por USG)
  - melhoram a eficácia do método no estadiamento

ALBERT EINSTEIN
HOSPITAL ISRAELITA

RM no estadiamento local

- **Sinais de extensão extraprostática**

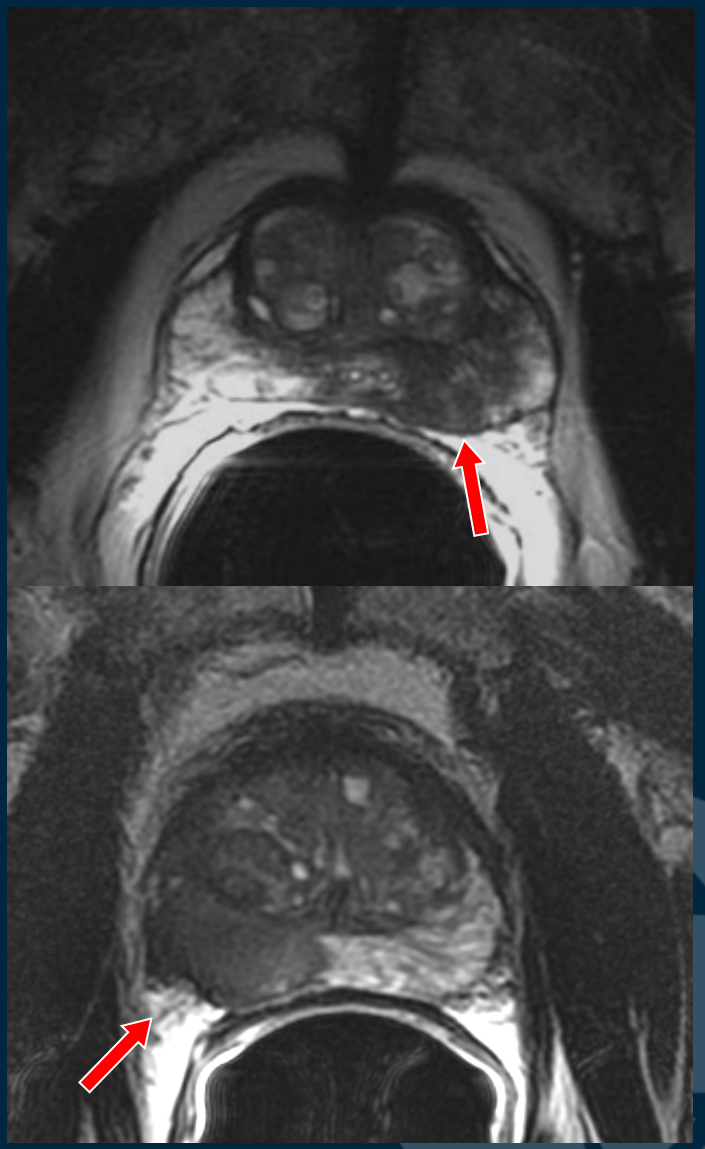

ALBERT EINSTEIN
HOSPITAL ISRAELITA

RM no estadiamento local

- Invasão de vesículas seminais

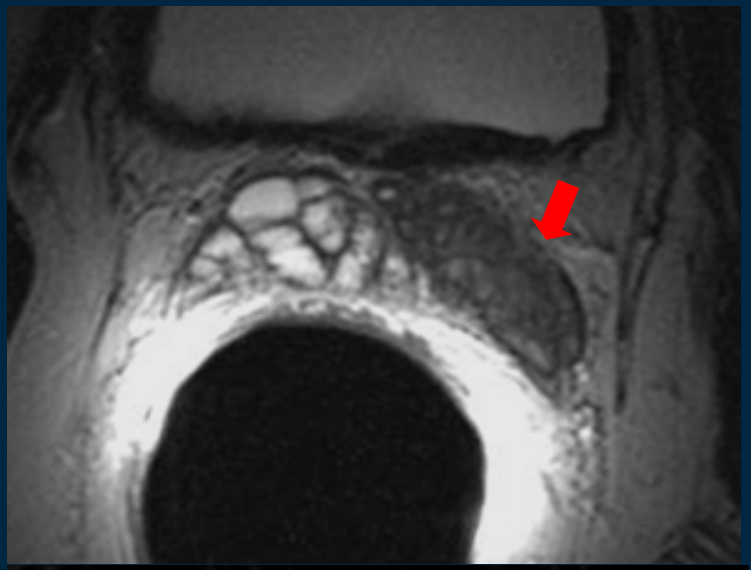

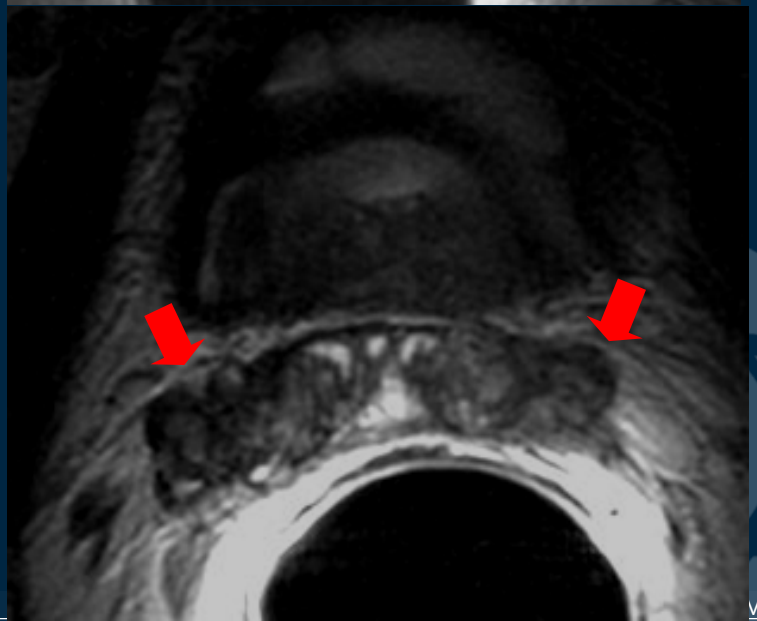

Nomogramas: valor incremental da RM

Liang Wang, MD, Michael W. Kattan, PhD, Peter T. Scardino, MD and Hedvig Hricak, MD, PhD

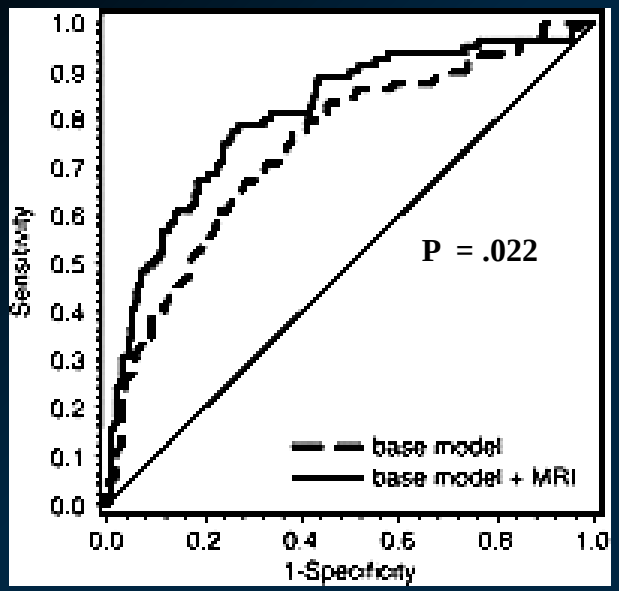

- Predição de extensão extracapsular
- 344 pacientes
- RM: melhor variável na análise univariada e multivariada

Radiology 2004;232:133-139

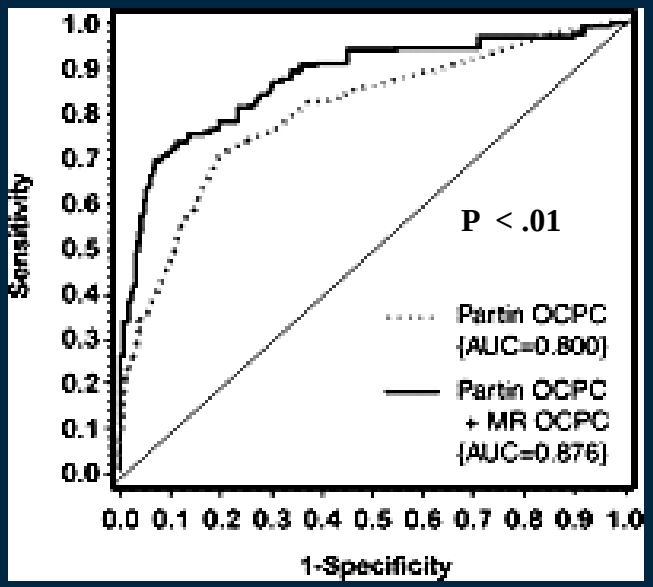

- Predição de doença órgão confinada
- 229 pacientes
- RM ainda melhor para pacientes de risco intermediário e alto

Radiology 2006;238:597-603

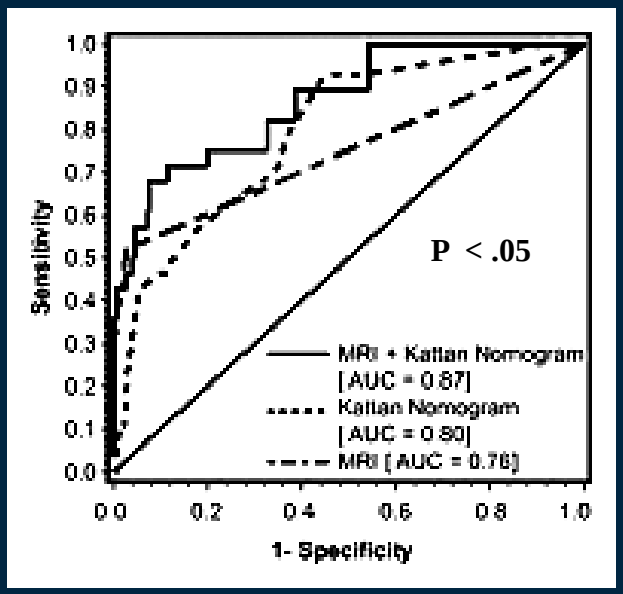

- Predição de invasão de VVSS
- 573 pacientes
- RM: maior curva ROC dentre todas as variáveis isoladas

Radiology 2006;242:182-188

Rastreamento de tumor de próstata hoje…

- TR alterado
- PSA: > 2,5 ng/ml

BIÓPSIA DE PRÓSTATA

- 1 milhão de biópsias prostáticas anuais são realizadas nos EUA
- A técnica randomizada em sextantes ainda é a mais utilizada (até 16 fragmentos).
- Biópsia prostática randomizada pode não detectar tumor em até 30-60 % dos casos
- Até 50% dos CaP diagnosticados não são clinicamente significantes

Estadio clínico T1 c
Densidade PSA < 0.15 ng/mL
Sem Gleason 4 ou 5
Até 3 fragmentos < 50%

J Urol 2002;167:2435-2439
J Urol 2001;165:1554-1559
J Urol, 2003169(1) 12-19.

RM MULTIPARAMÉTRICA

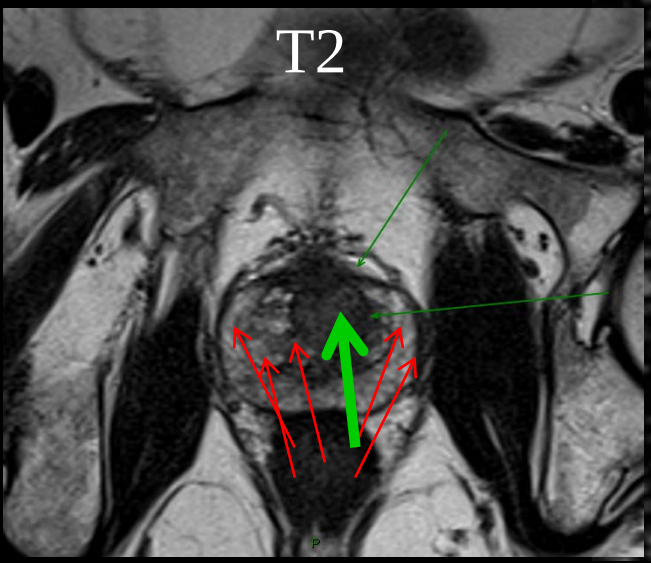

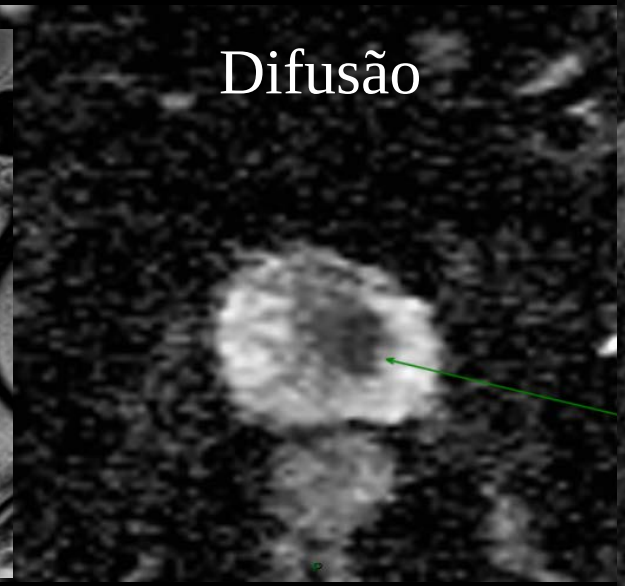

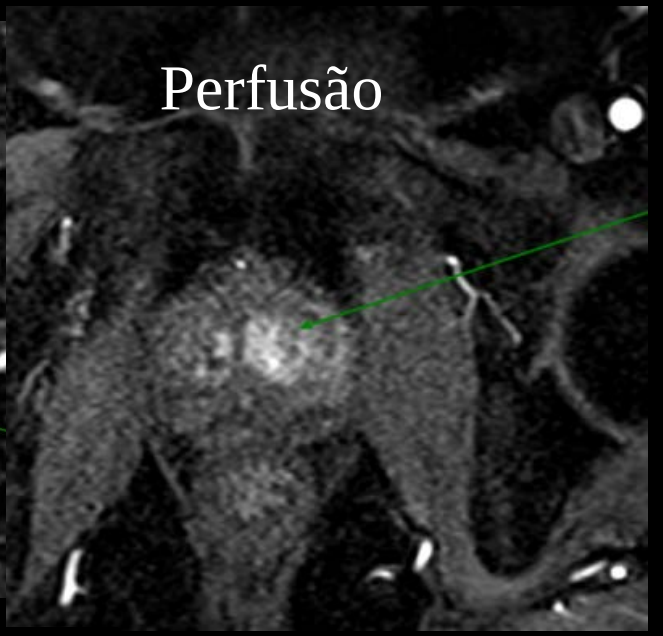

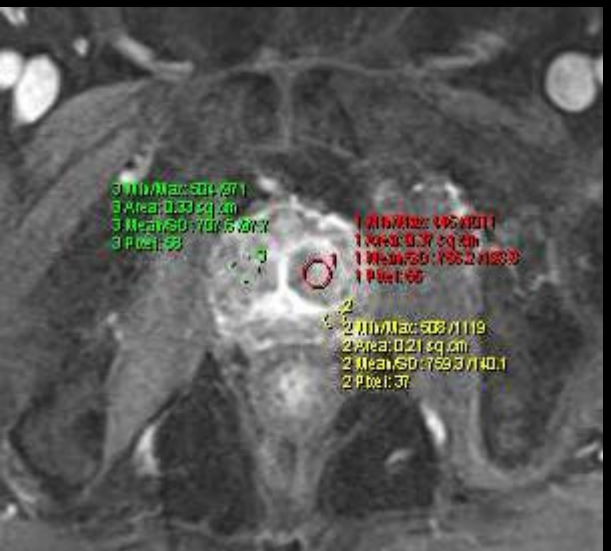

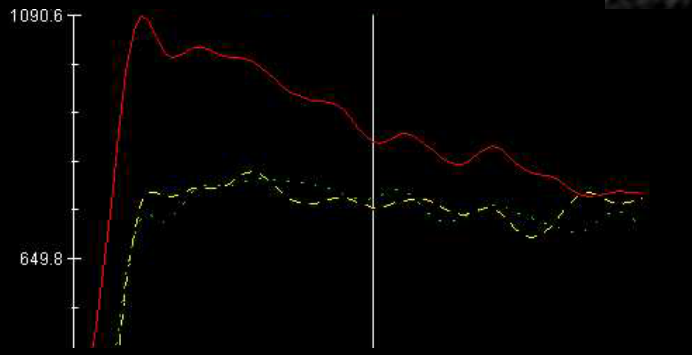

AP: Adenoca Gleason 8 (5 + 3)

EURURO-8298; No. of Pages 12
ARTICLE IN PRESS
EUROPEAN UROLOGY XXX (2019) XXX–XXX

available at www.sciencedirect.com
journal homepage: www.europeanurology.com

European Association of Urology

Platinum Priority – Review – Prostate Cancer

Editorial by XXX on pp. x–y of this issue

Prostate Imaging Reporting and Data System Version 2.1: 2019 Update of Prostate Imaging Reporting and Data System Version 2

Baris Turkbey[a,†,], Andrew B. Rosenkrantz[b,†,*], Masoom A. Haider[c], Anwar R. Padhani[d], Geert Villeirs[e], Katarzyna J. Macura[f], Clare M. Tempany[g], Peter L. Choyke[a], Francois Cornud[h], Daniel J. Margolis[i], Harriet C. Thoeny[j], Sadhna Verma[k], Jelle Barentsz[l,‡], Jeffrey C. Weinreb[m,‡]*

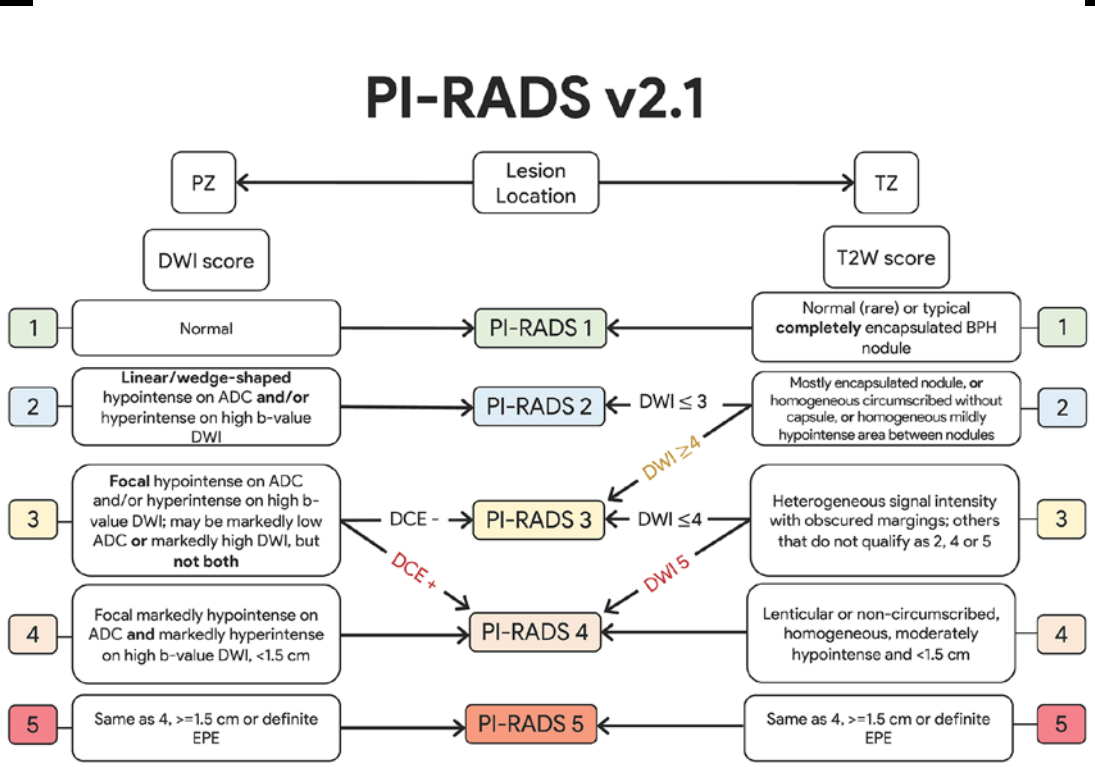

PIRADS 1

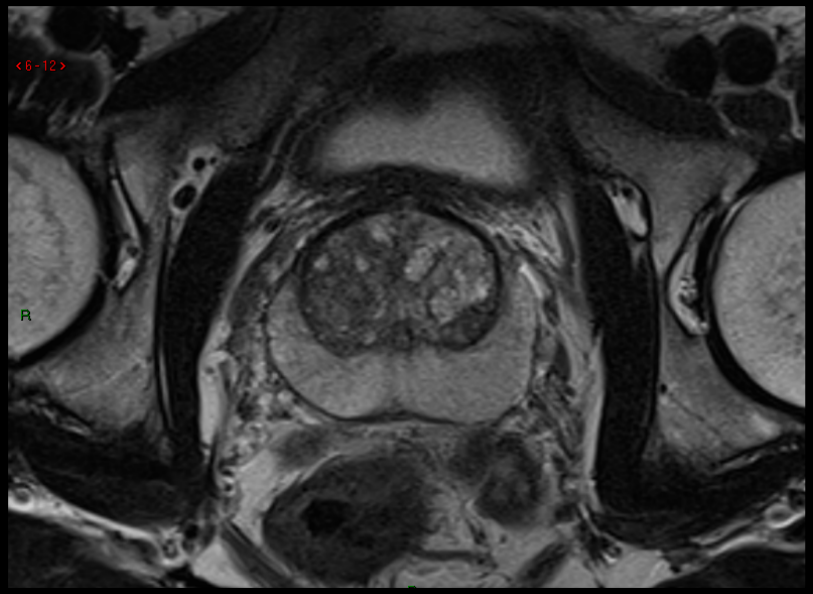

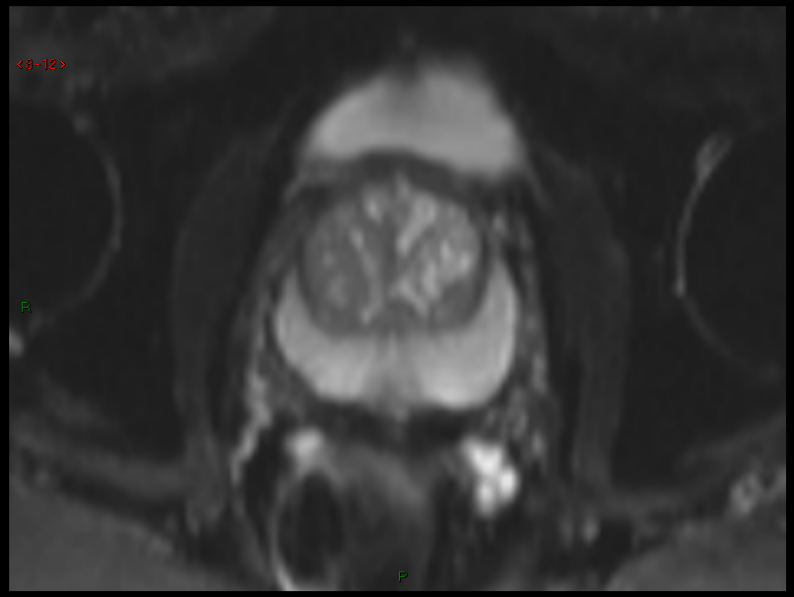

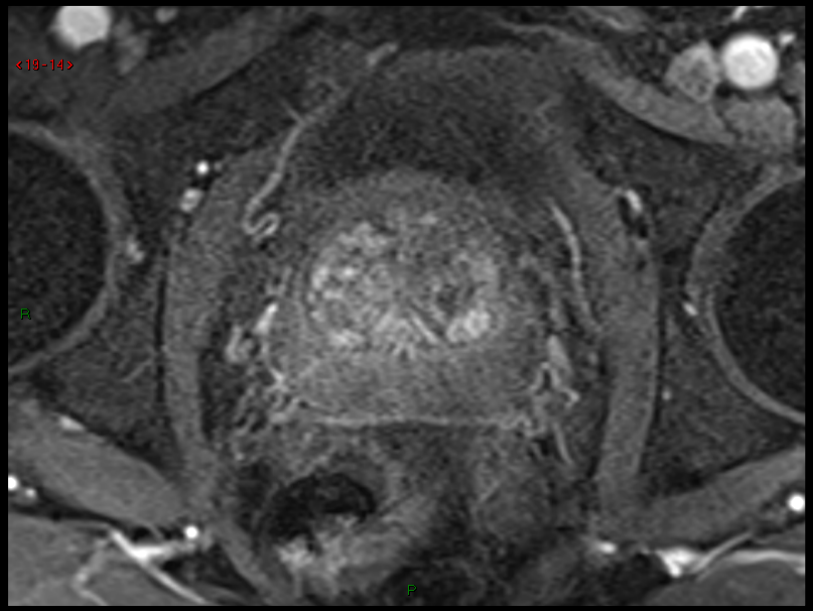

PIRADS 2

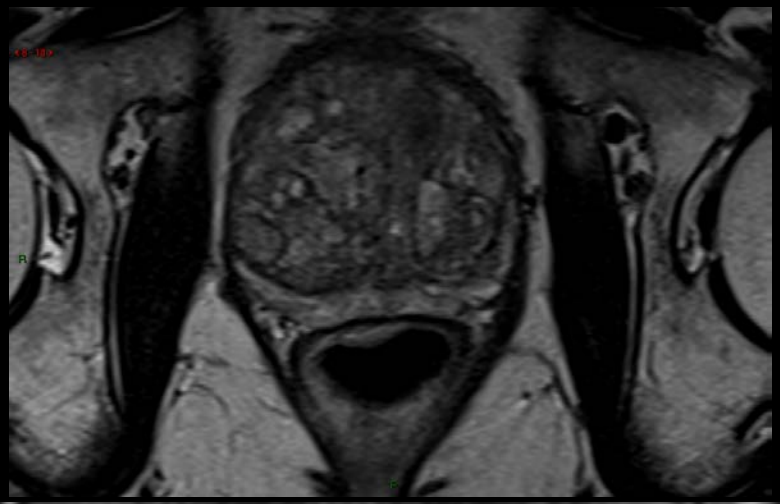

PIRADS 3

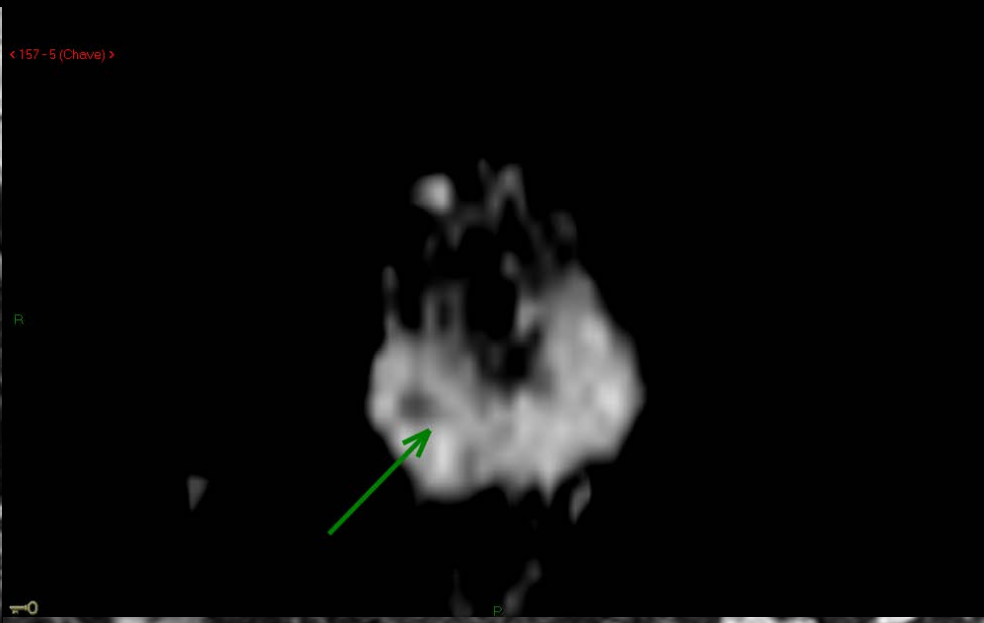

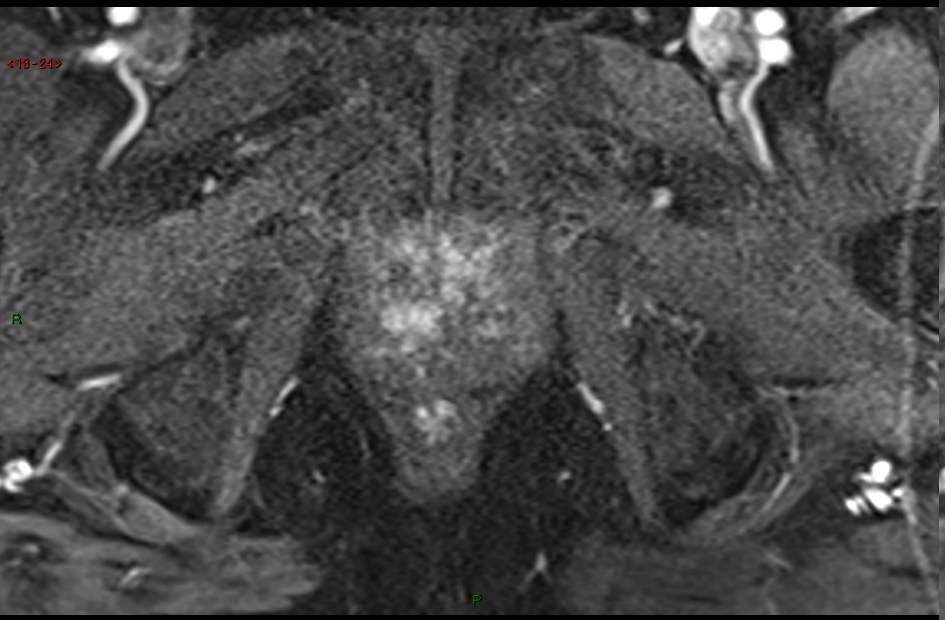

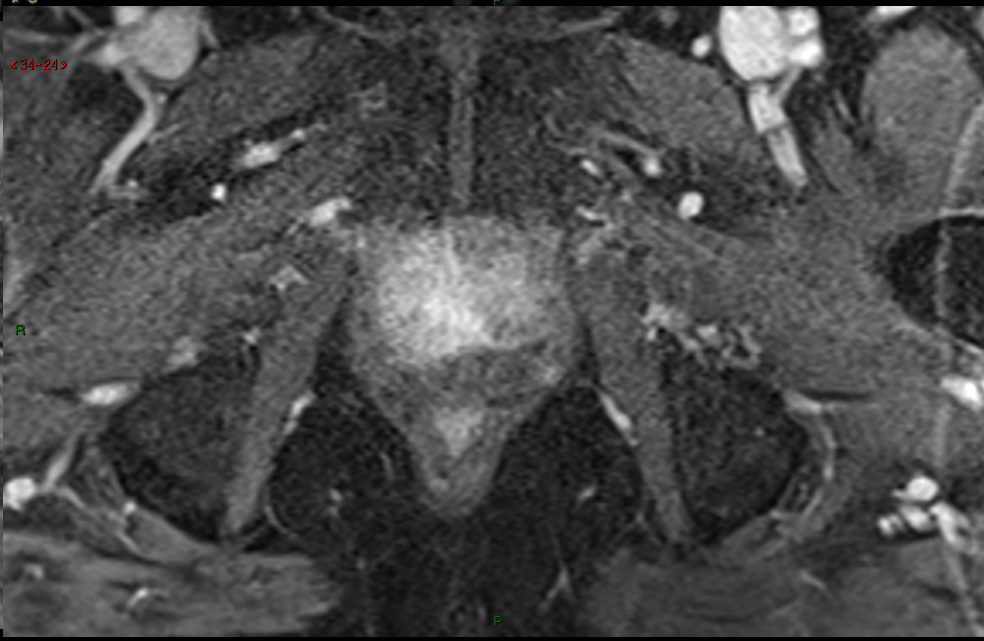

PIRADS 4

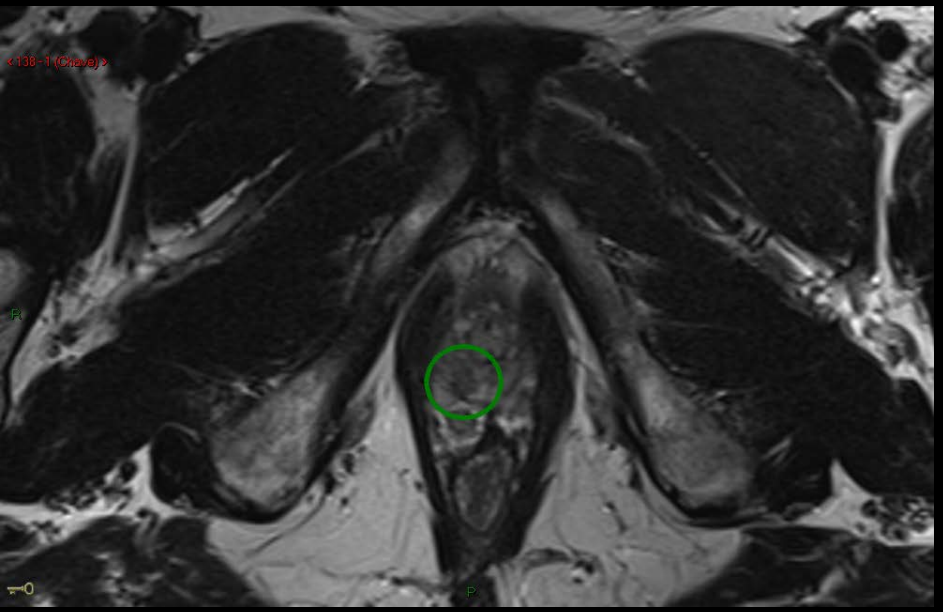

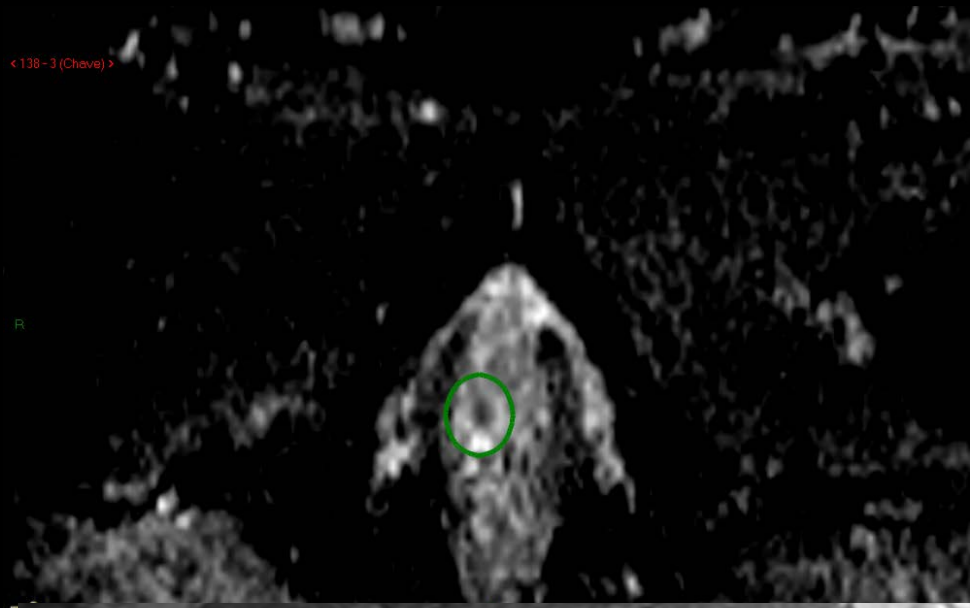

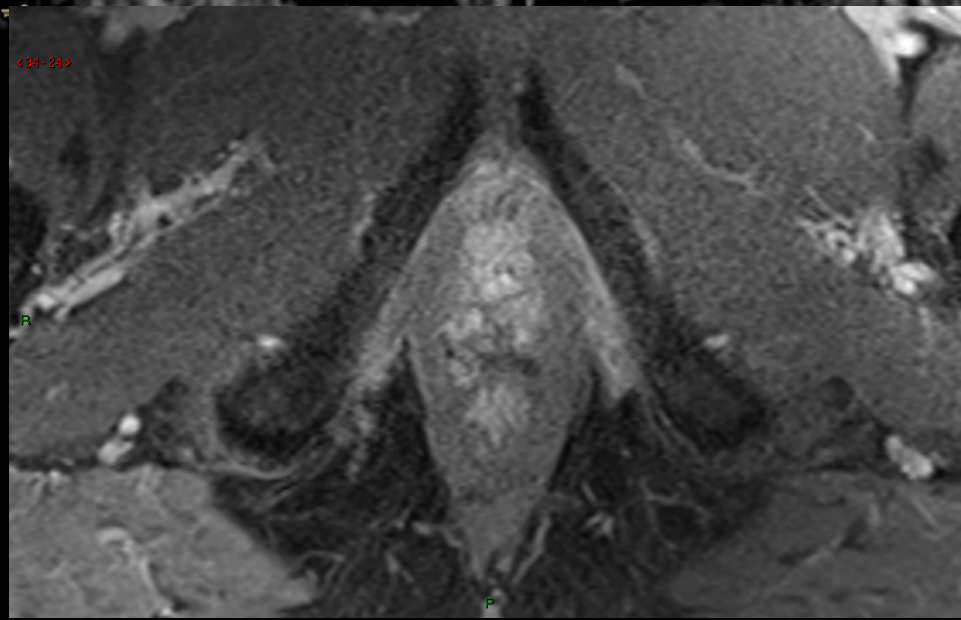

PIRADS 5

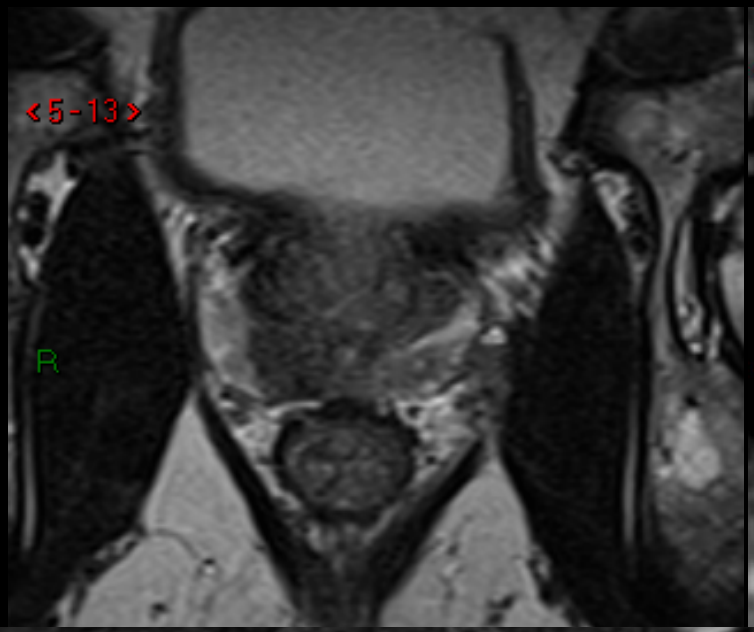

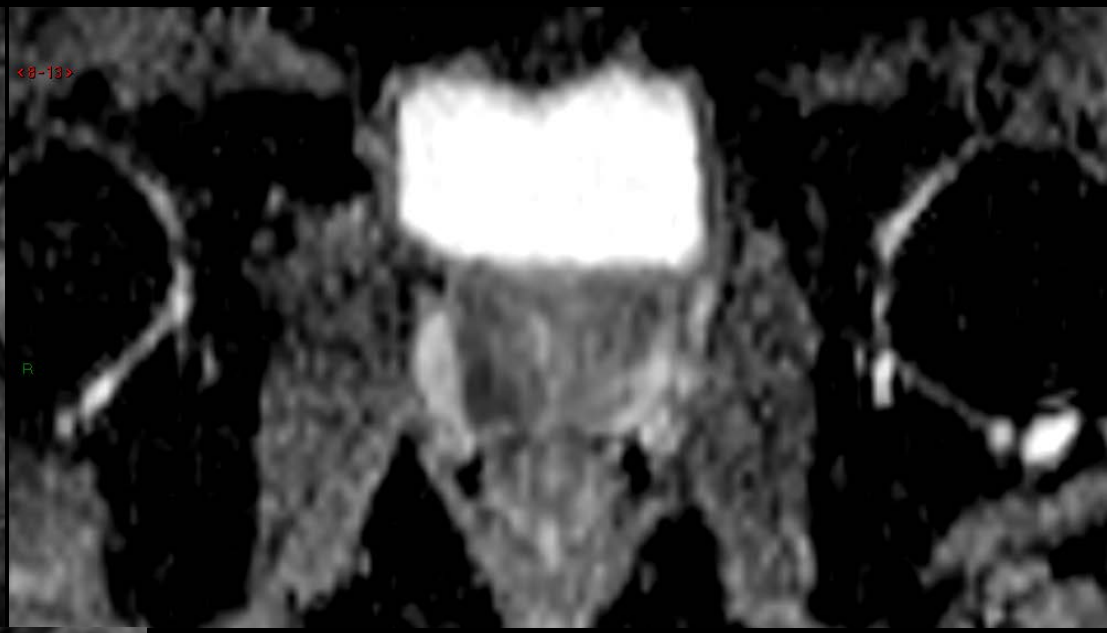

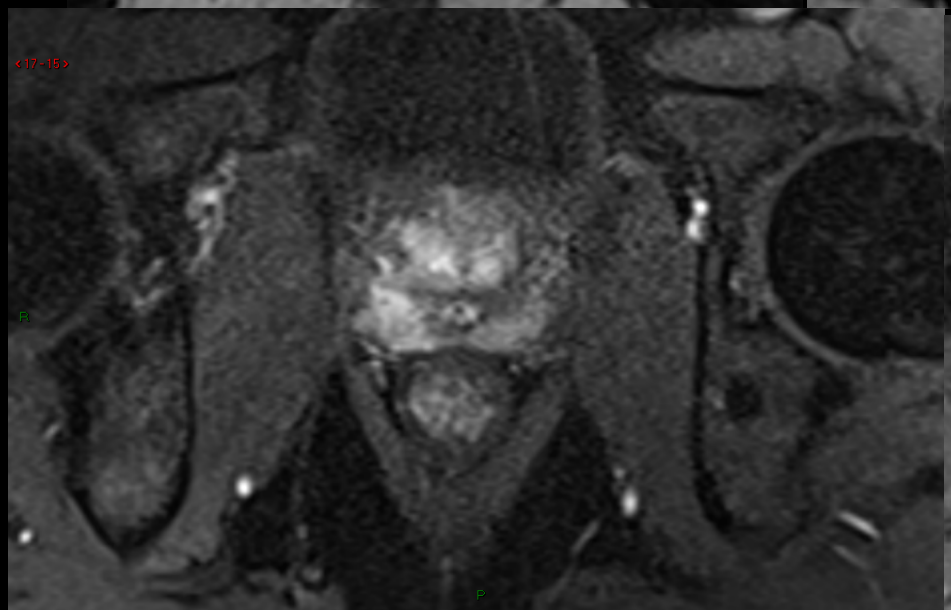

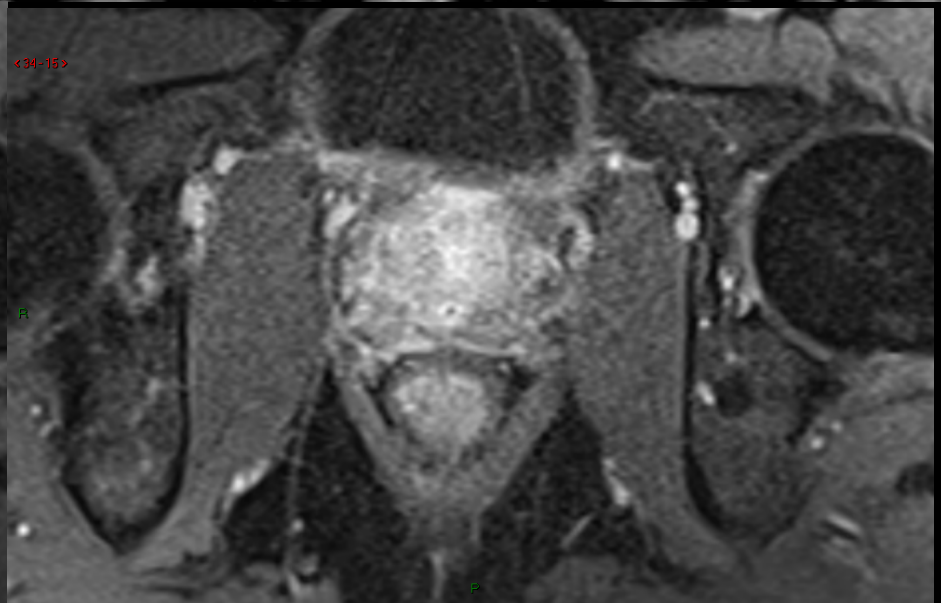

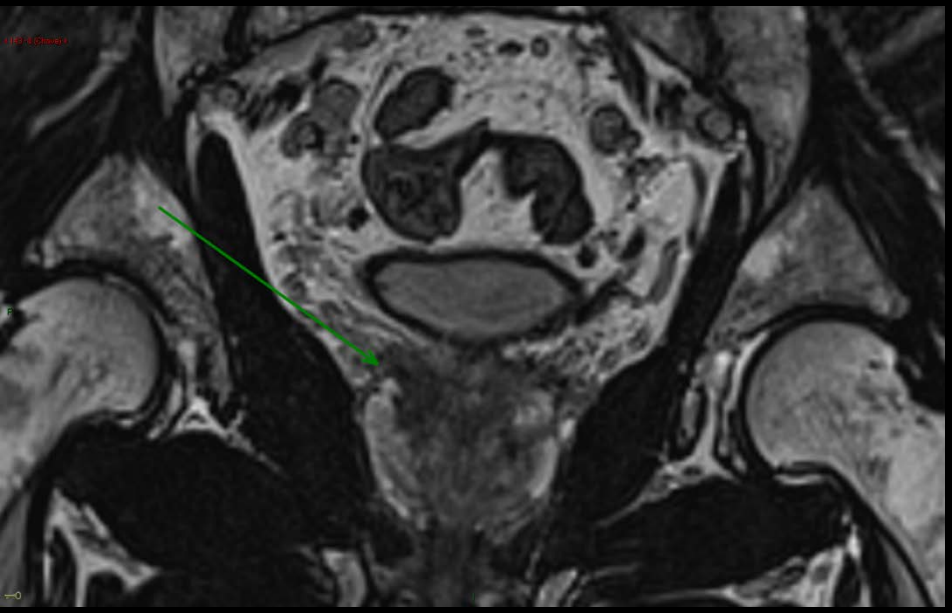

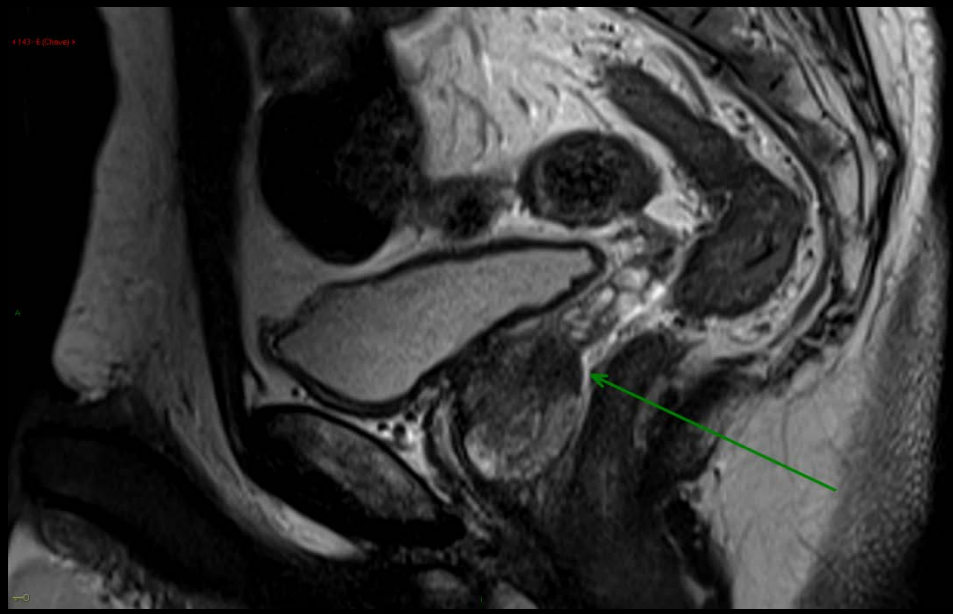

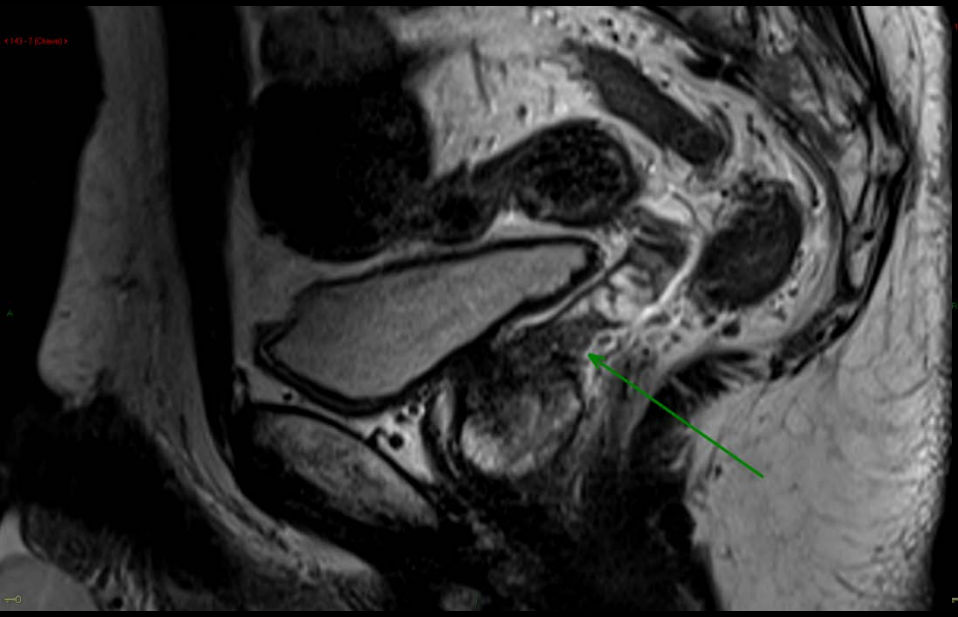

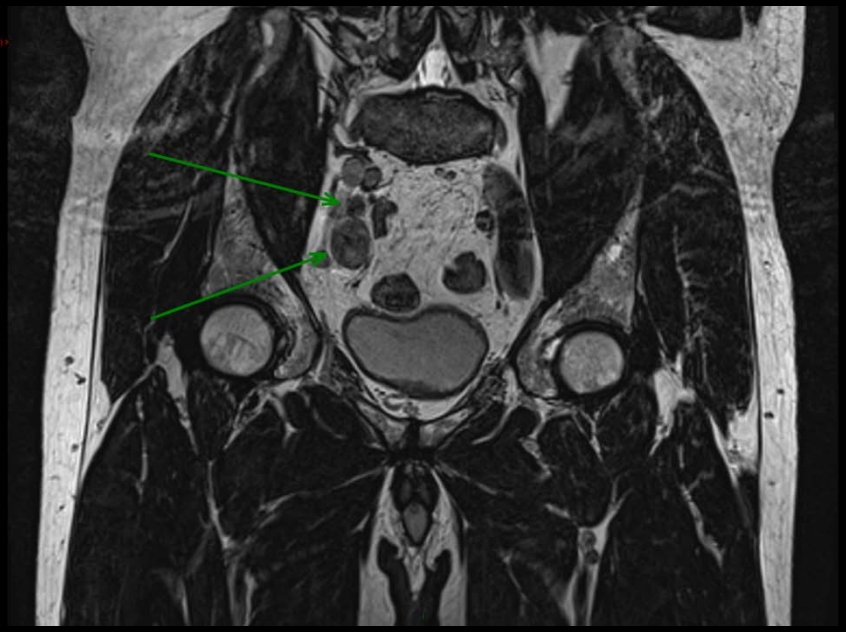

PIRADS 5

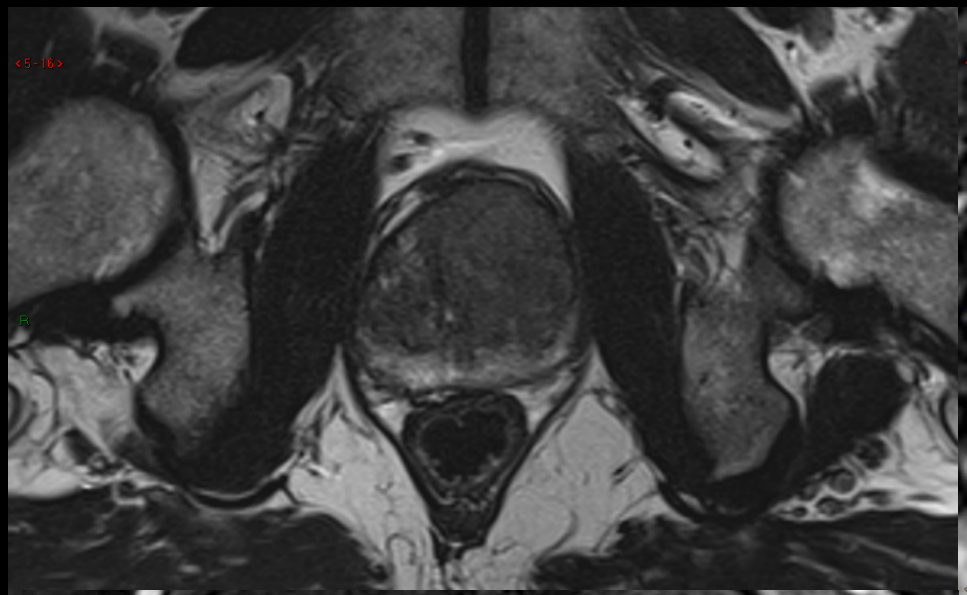

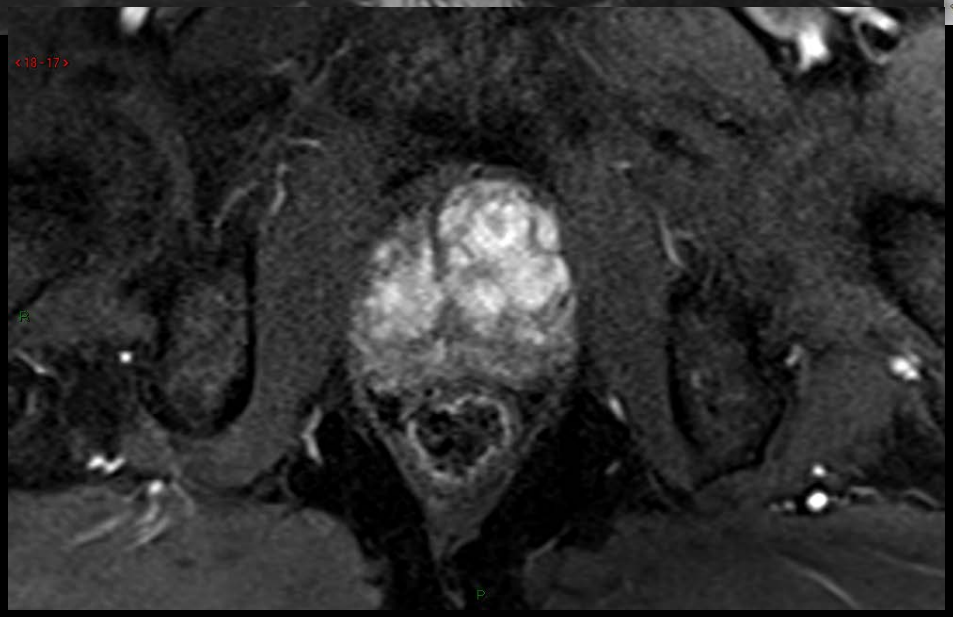

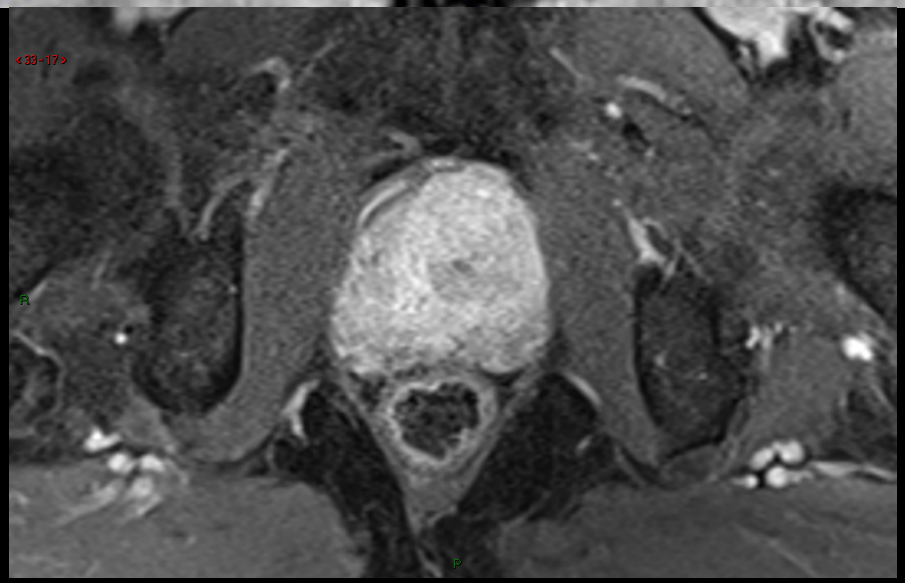

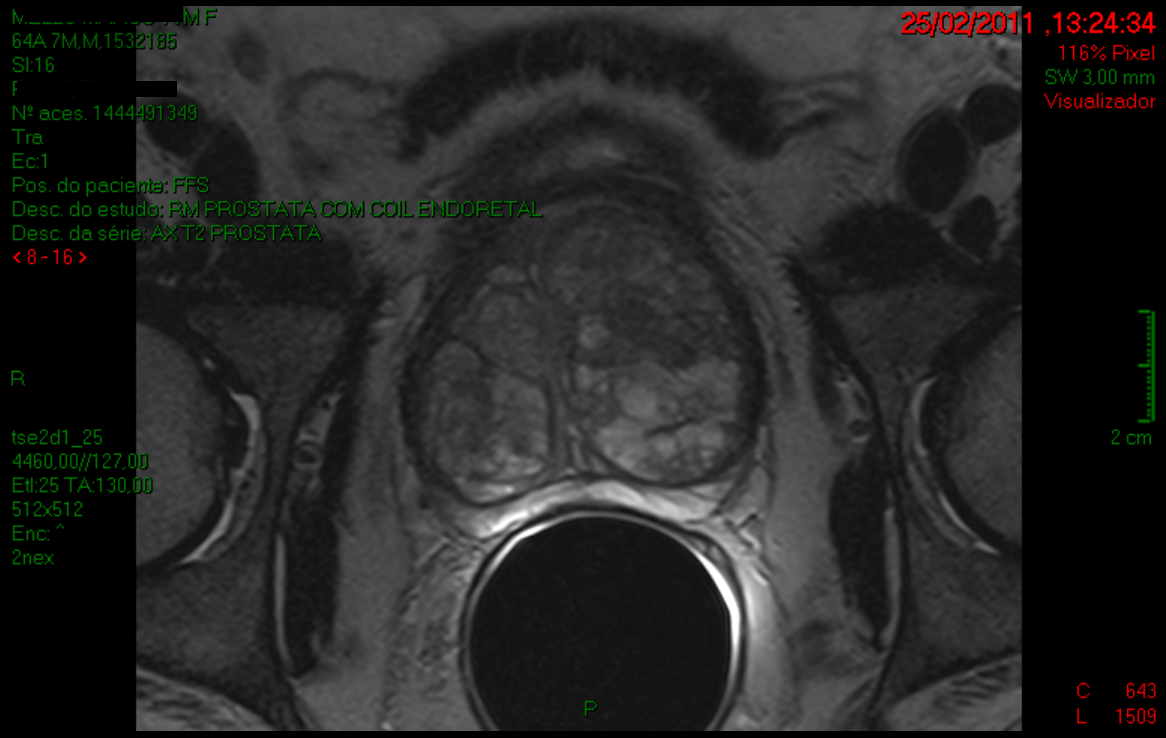

1,5T
com bobina

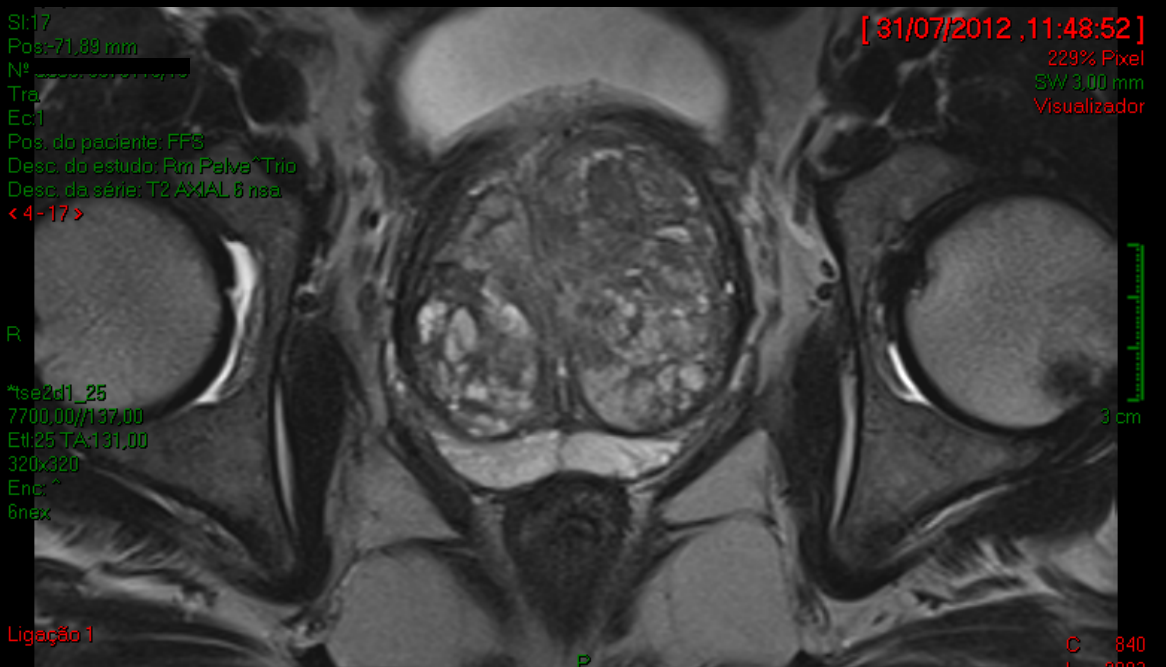

3T
sem bobina

[1] Sosna J, et al. Academic Radiology 2004; 11(8): 857-862
[2] Miao et al. Eur J Radiol. 2007 Feb;61(2):297-302

Biópsia com fusão de imagens USG + RM

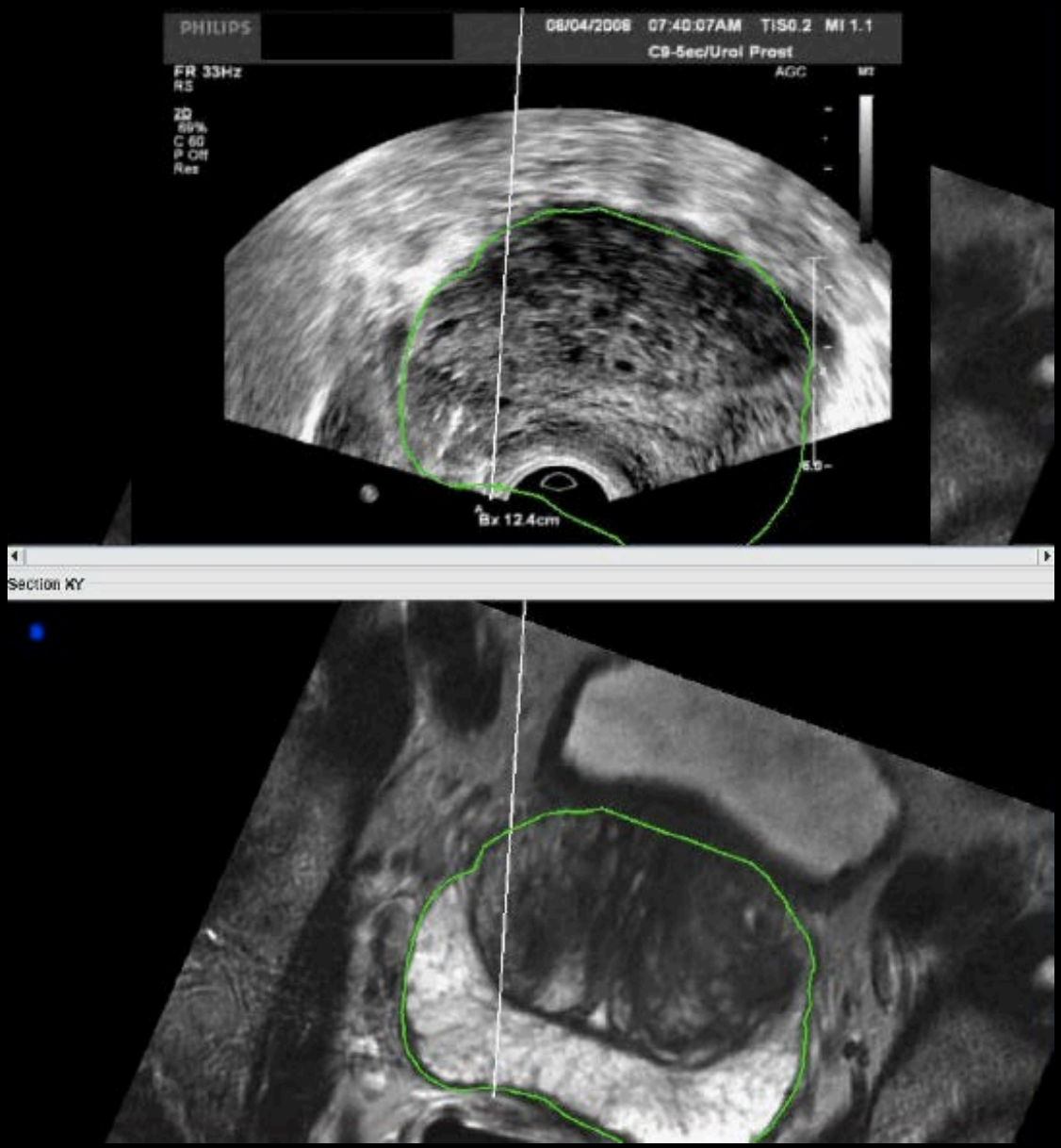

Paciente 64 anos, elevação PSA, toque normal

	07/04/2011	21/08/2013
PSA total (ng/ml)	7,2	14,2
%PSA livre	8	8

Biopsia prévia negativa (08/06/2012)

PEÇAS RADICAIS E PUNÇÕES
Exame Anatomopatológico

Espécimes e Procedimentos

Próstata, biópsias seriadas por agulha

Microscopia e Conclusões
Diagnósticas

Negativo para neoplasia (todas as amostras)
Atrofia glandular multifocal
Prostatite crônica não específica com focos de atividade aguda

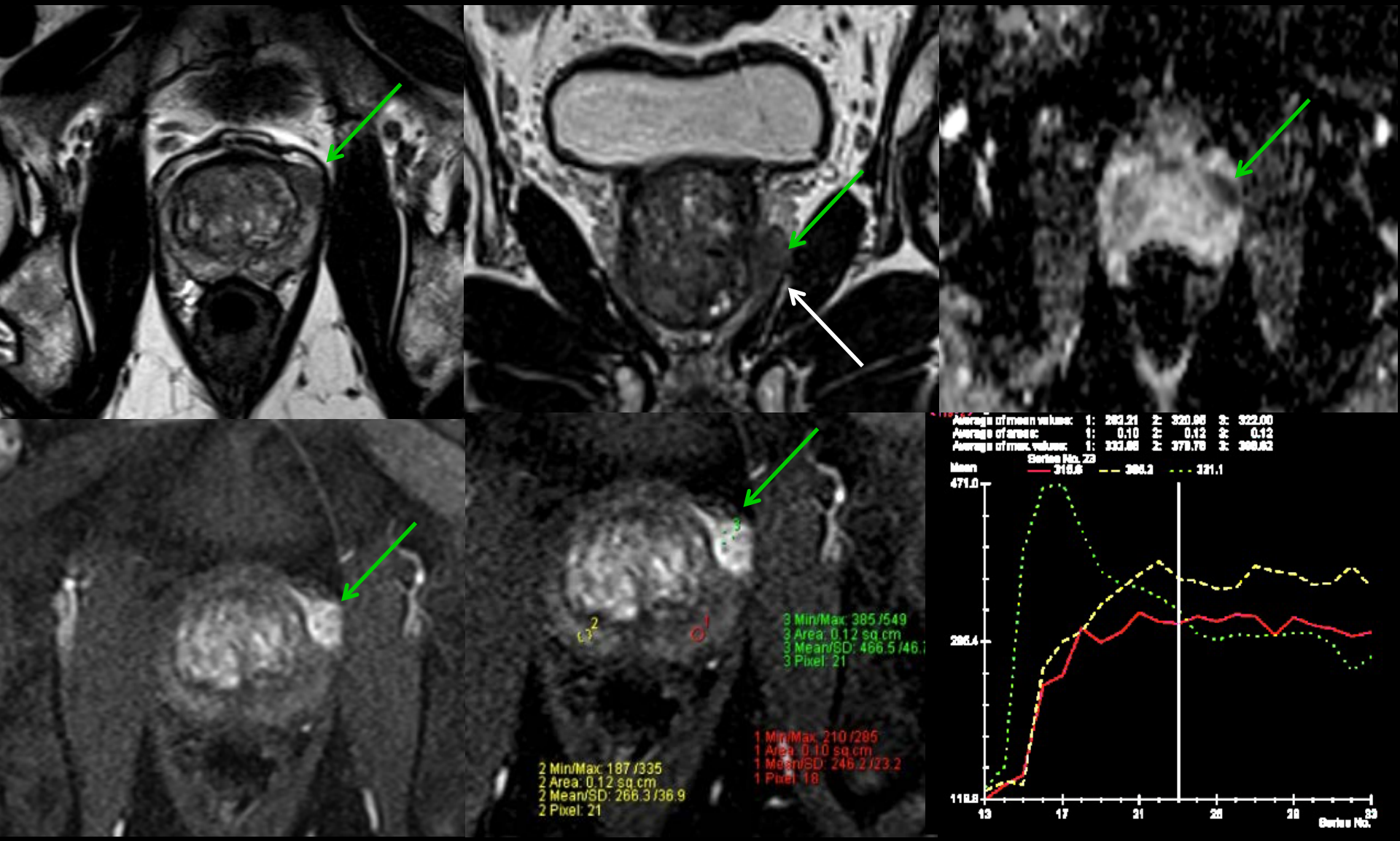
3 Min/Max: 385 /549
3 Area: 0.12 sq.cm
3 Mean/SD: 466.5 /46.
3 Pixel: 21
1 Min/Max: 210 /285
1 Area: 0.10 sq.cm
1 Mean/SD: 246.2 /23.2
1 Pixel: 18
2 Min/Max: 187 /335
2 Area: 0.12 sq.cm
2 Mean/SD: 266.3 /36.9
2 Pixel: 21
Mean
471.0
296.4
13
17
31
Series No.

PIRADS 4

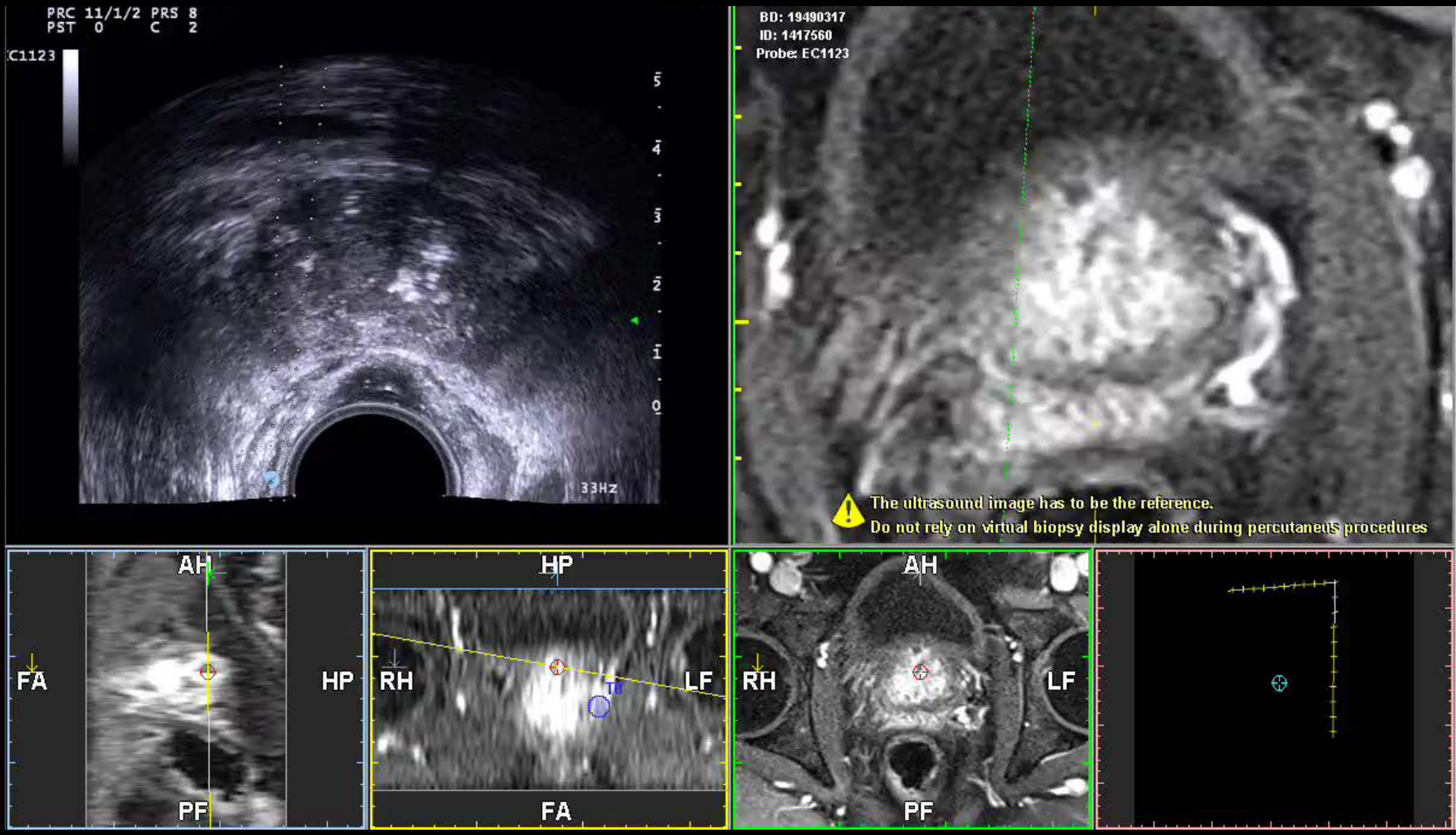
PRC 11/1/2 PRS 8
PST 0 C 2
C1123
5
4
3
2
1
0
33Hz
BD: 19490317
ID: 1417560
Probe: EC1123
The ultrasound image has to be the reference.
Do not rely on virtual biopsy display alone during percutaneus procedures
AH
FA
HP
PF
HP
RH
LF
FA
AH
RH
LF
PF

- BIÓPSIA (04/09/2013)

  Adenocarcinoma usual

- Gleason 8 (4+4)

  ZPE ML 23%,

  Nódulo lobo esquerdo 50%

- PROSTATECTOMIA (07/10/13)
- Anatomopatológico

  - Gleason 9 (4 +5), 15% tecido prostático

  - infiltração perineural: presente

  - extensão extraprostática: não detectada

  - vesículas seminais: livres

  - linfonodos: negativos (00/04)

ESTADIAMENTO: pT2c pN0

EUROPEAN UROLOGY 67 (2015) 1112–1121

available at www.sciencedirect.com
journal homepage: www.europeanurology.com

European Association of Urology

Review – Prostate Cancer

Use of the Prostate Imaging Reporting and Data System (PI-RADS) for Prostate Cancer Detection with Multiparametric Magnetic Resonance Imaging: A Diagnostic Meta-analysis

Esther H.J. Hamoen [a,b,*], *Maarten de Rooij* [b,c], *J. Alfred Witjes* [a], *Jelle O. Barentsz* [b], *Maroeska M. Rovers* [c,d]

Studies	Pooled performance value (95% CI) Sensitivity	Specificity
All studies	0.78 (0.70 – 0.84)	0.79 (0.68 – 0.86)
Studies accurately using PI-RADS	0.82 (0.72 – 0.89)	0.82 (0.67 – 0.92)
Studies doubtful using PI-RADS	0.73 (0.62 – 0.82)	0.74 (0.61 – 0.84)
Studies that reported data by patient	0.81 (0.72 – 0.87)	0.74 (0.59 – 0.85)
Studies that reported data on any cancer	0.74 (0.67 – 0.81)	0.80 (0.70 – 0.88)
Studies that reported data on significant cancer	0.84 (0.76 – 0.89)	0.75 (0.66 – 0.83)
Studies with a good reference standard	0.76 (0.66 – 0.84)	0.77 (0.64 – 0.87)
Studies with a less good reference standard	0.82 (0.71 – 0.89)	0.82 (0.64 – 0.92)
Studies including patients without previous biopsies	0.71 (0.48 – 0.86)	0.77 (0.70 – 0.83)
Studies including patients with at least one previous biopsy	0.80 (0.65 –0.90)	0.78 (0.63 – 0.89)
Studies including patients with and without previous biopsies	0.81 (0.67 – 0.90)	0.72 (0.48 – 0.88)
Studies using a PI-RADS sum score	0.80 (0.72 – 0.87)	0.82 (0.69 – 0.91)
Studies using a PI-RADS overall 5-point score	0.76 (0.59 – 0.87)	0.73 (0.61 – 0.82)

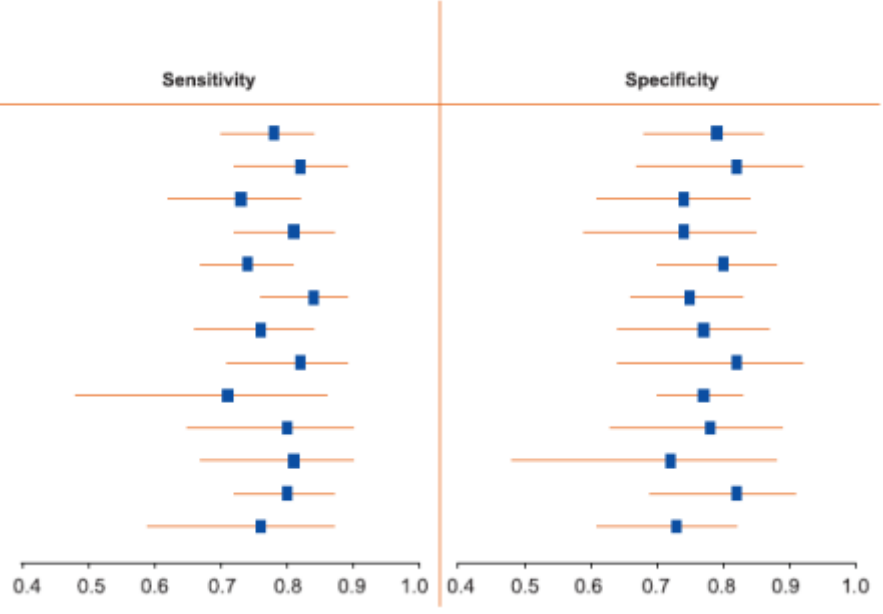

ALBERT EINSTEIN
HOSPITAL ISRAELITA

RMmp x biópsia com fusão (2013 a 2018)

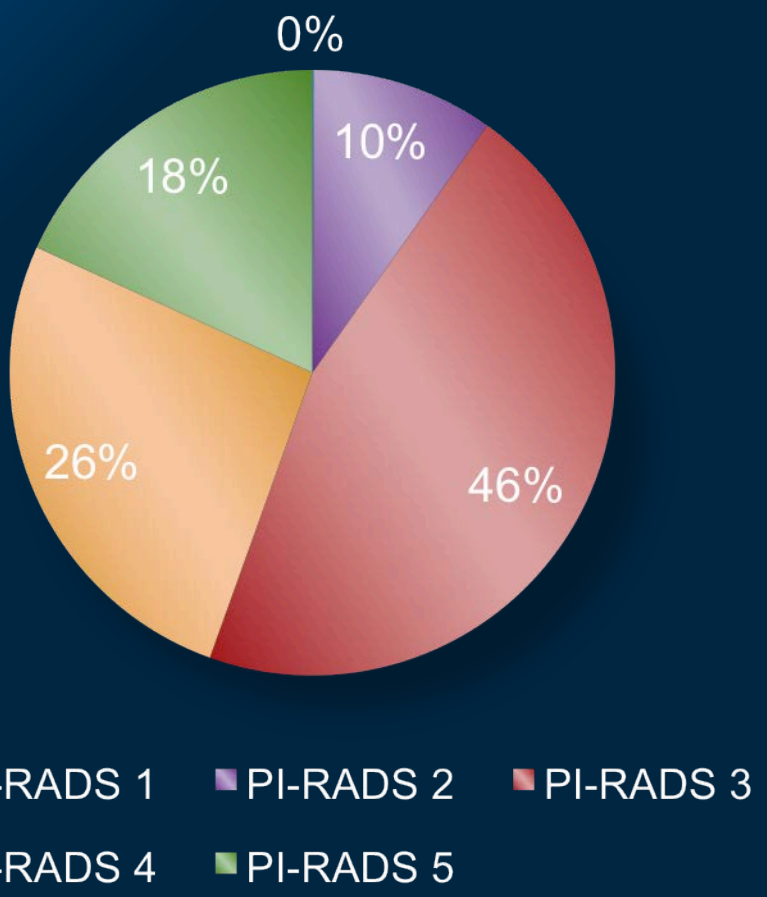

PI-RADS	RM
1	1 (0,1%)
2	106 (9,7%)
3	501 (45,7%)
4	289 (26,3%)
5	200 (18,2%)
TOTAL	1097 casos

ALBERT EINSTEIN
HOSPITAL ISRAELITA

RMmp x biópsia com fusão (2013 a 2018)

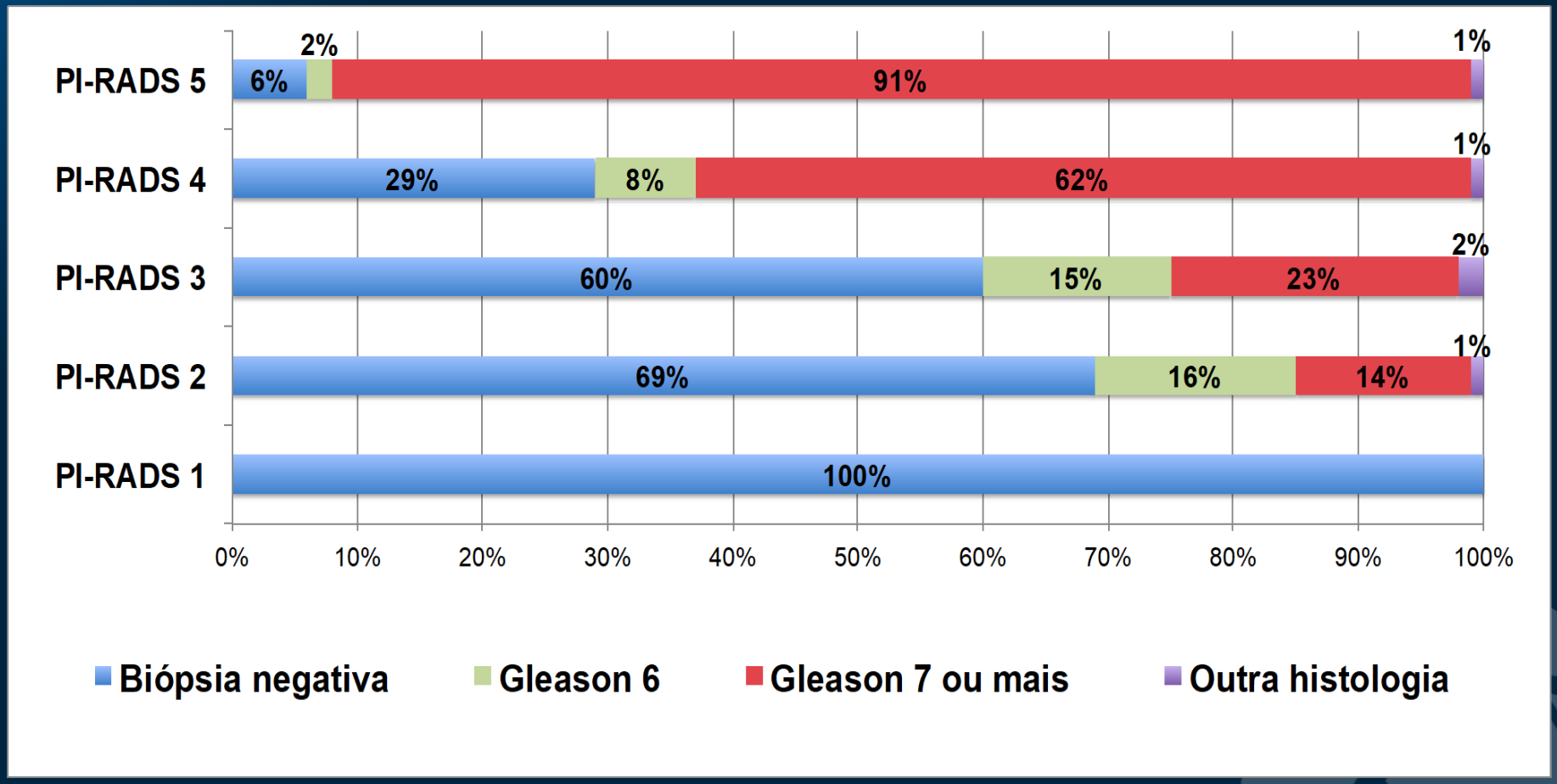

Eur J Radiol. 2014 Oct;83(10):1740-5. doi: 10.1016/j.ejrad.2014.06.026. Epub 2014 Jul 3.

Negative predictive value of multiparametric MRI for prostate cancer detection: outcome of 5-year follow-up in men with negative findings on initial MRI studies.

Itatani R[1], Namimoto T[2], Atsuji S[3], Katahira K[3], Morishita S[3], Kitani K[4], Hamada Y[4], Kitaoka M[5], Nakaura T[6], Yamashita Y[2].

Author information

Abstract

OBJECTIVE: To assess the clinical negative predictive value (NPV) of multiparametric MRI (mp-MRI) for prostate cancer in a 5-year follow-up.

MATERIALS AND METHODS: One hundred ninety-three men suspected of harboring prostate cancer with negative MRI findings were included. Patients with positive transrectal ultrasound (TRUS)-guided biopsy findings were defined as false-negative. Patients with negative initial TRUS-guided biopsy findings were followed up and only patients with negative findings by digital rectal examination, MRI, and repeat biopsy and no increase in PSA at 5-year follow-up were defined as "clinically negative". The clinical NPV of mp-MRI was calculated. For quantitative analysis, mean signal intensity on T2-weighted images and the mean apparent diffusion coefficient value on ADC maps of the initial MRI studies were compared between peripheral-zone (PZ) cancer and the normal PZ based on pathologic maps of patients who had undergone radical prostatectomy.

RESULTS: The clinical NPV of mp-MRI was 89.6% for significant prostate cancer. Small cancers, prostatitis, and benign prostatic hypertrophy masking prostate cancer returned false-negative results. Quantitative analysis showed that there was no significant difference between PZ cancer and the normal PZ.

CONCLUSION: The mp-MRI revealed a high clinical NPV and is a useful tool to rule out clinically significant prostate cancer before biopsy.

Published online before print
March 6, 2013, doi:
10.1148/radiol.13121325

Prostate Cancer: Can Multiparametric MR Imaging Help Identify Patients Who Are Candidates for Active Surveillance?

Baris Turkbey, MD, Haresh Mani, MD, Omer Aras, MD, Jennifer Ho, Anthony Hoang, MD, Ardeshir R. Rastinehad, DO, Harsh Agarwal, PhD, Vijay Shah, PhD, Marcelino Bernardo, BS, Yuxi Pang, PhD, Dagane Daar, RT, Yolanda L. McKinney, RN, W. Marston Linehan, MD, Aradhana Kaushal, MD, Maria J. Merino, MD, Bradford J. Wood, MD, Peter A. Pinto, MD and Peter L. Choyke, MD

Results: Among 133 patients, 14 were eligible for AS on the basis of prostatectomy results. The sensitivity, positive predictive value (PPV), and overall accuracy, respectively, were 93%, 25%, and 70% for the D'Amico system, 64%, 45%, and 88% for the Epstein criteria, and 93%, 20%, and 59% for the CAPRA scoring system for predicting AS candidates ($P < .005$ for all, χ^2 test), while multiparametric MR imaging had a sensitivity of 93%, a PPV of 57%, and an overall accuracy of 92% ($P < .005$).

Conclusion: Multiparametric MR imaging provides useful additional information to existing clinicopathologic scoring systems of prostate cancer and improves the assignment of treatment (eg, AS or active treatment).

PSA 4,6 sem biópsia prévia

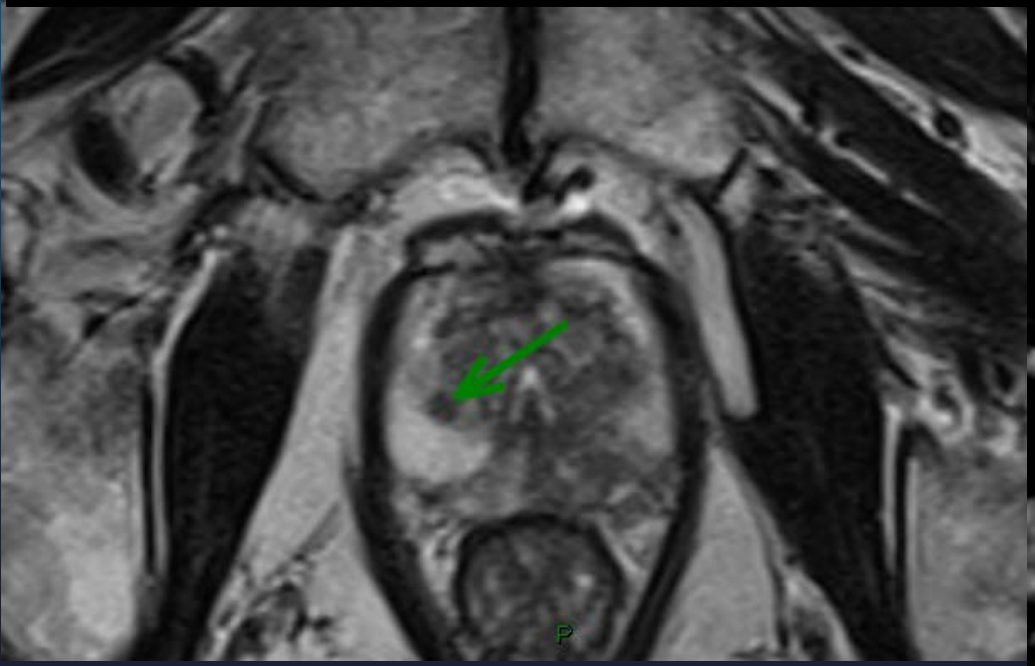

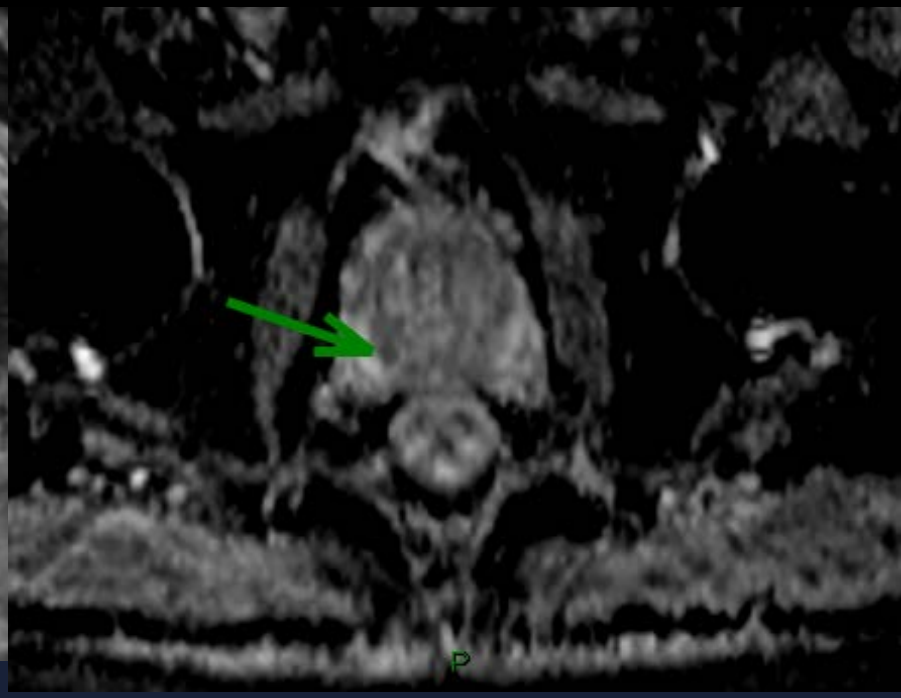

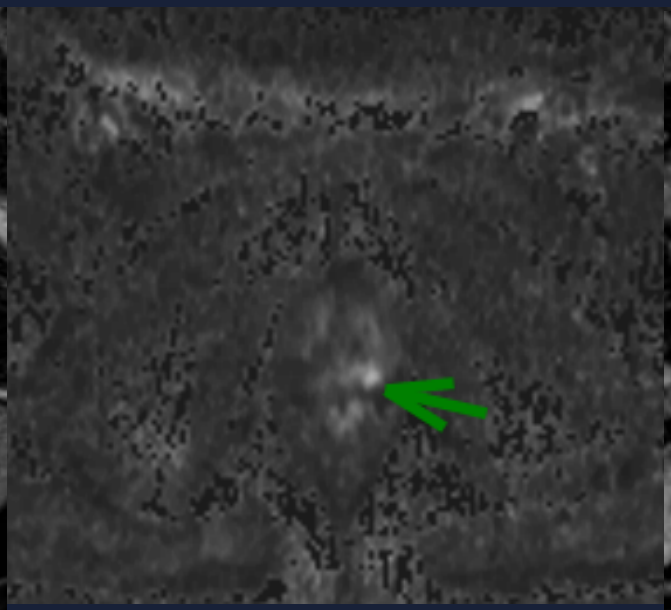

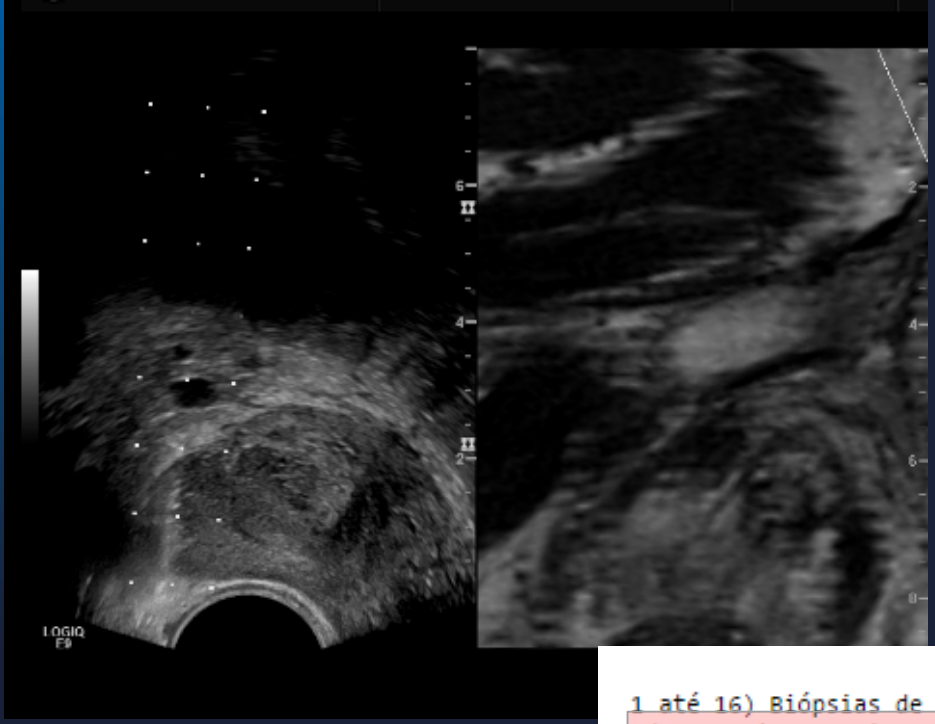

1 até 16) Biópsias de próstata:
Adenocarcinoma acinar usual da próstata de Gleason 6 (3+3) focal, comprometendo (ver nota):
Zona periférica direita-base lateral (item 2): extensão linear máxima de 1,3 mm; cerca de 10% do cilindro prostático; neoplasia compromete 01 de 01 fragmento

Dados adicionais:
Porcentagem de cilindros prostáticos comprometidos pela neoplasia: 4,3% (01 em total de 23)
Infiltração perineural: não detectada
Infiltração angiolinfática: não detectada

Demais fragmentos prostáticos livres de comprometimento neoplásico.
Atrofia acinar focal
Foco com hiperplasia de células basais
Prostatite crônica inespecífica focal

Nota:
Se o estádio for T1c e a densidade do PSA for menor que 0,15 ng/ml, o presente achado pode corresponder a um tumor pequeno de acordo com os critérios de Epstein (Cancer 2004, 101:2001-5) e ou os critérios de Noguchi (J Urol 2001, 166: 104-109). De acordo com os critérios de Epstein, se aplicáveis no presente caso, o tumor, numa eventual prostatectomia radical, tem probabilidade de 91,6% de ter um volume inferior a 0,5cc. Já de acordo com os critérios de Noguchi, se aplicáveis ao presente caso, o tumor, numa eventual prostatectomia radical, tem uma probabilidade de 75% de ter um volume inferior a

8 meses depois, PSA aumentou discretamente....

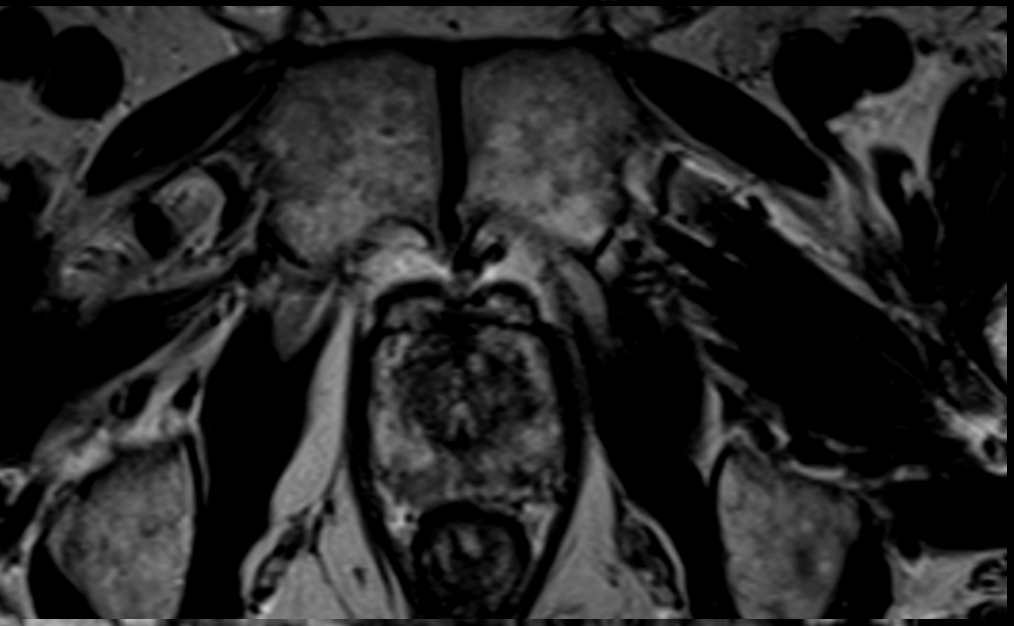

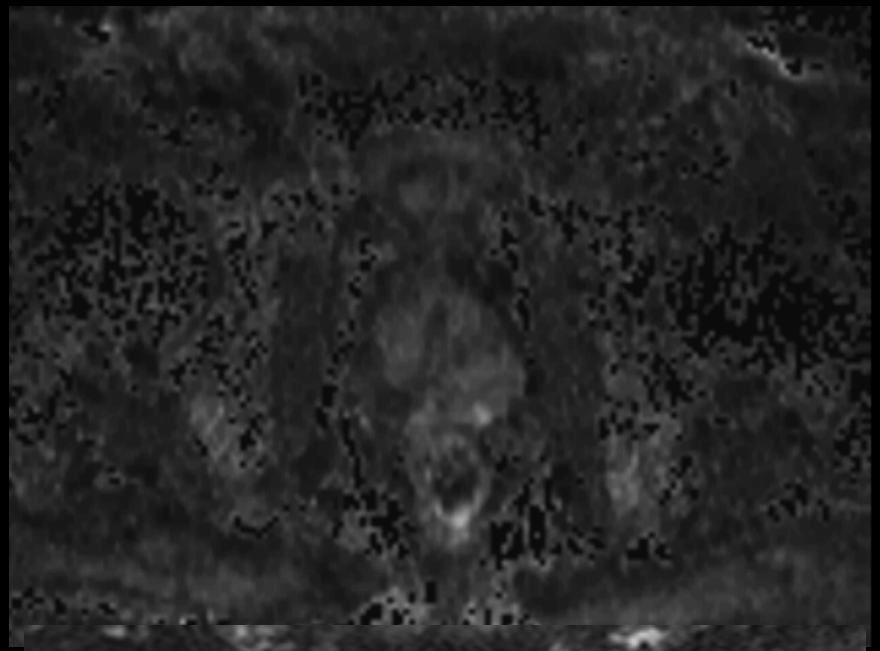

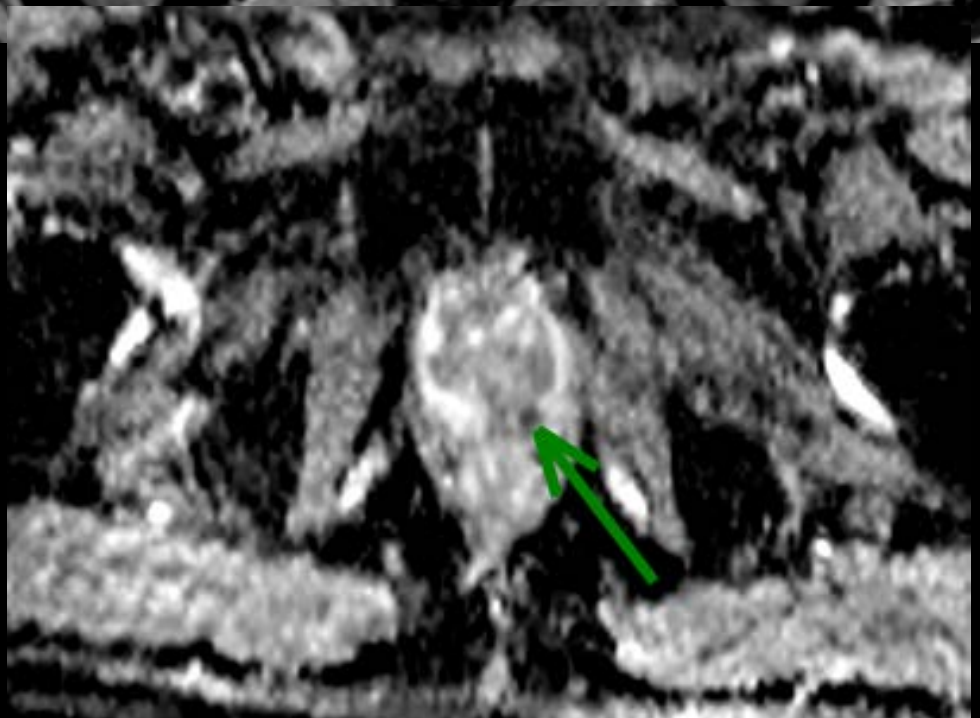

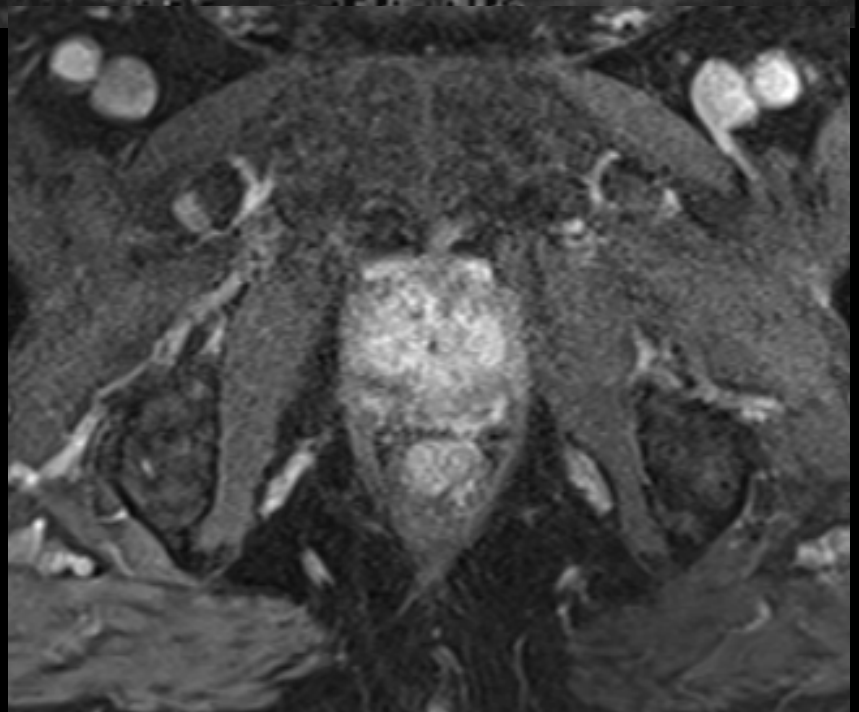

RESSONÂNCIA MAGNÉTICA MULTIPARAMÉTRICA DA PRÓSTATA

Sequências de alta resolução ponderadas em T2, difusão e perfusão em aparelho 3 Tesla.
Indicação clínica: reavaliação de paciente protocolo de vigilância ativa. Biópsia em 10/12/2014 com 1 fragmento positivo Gleason 6 na base direita.

Dimensões da próstata: 5,1 x 3,9 x 4,9 cm. Peso estimado em 51 gramas.

Glândula central: heterogênea a custa de nódulos de provável hiperplasia.

Zona periférica: sinal levemente heterogêneo em T2, destacando-se nódulo bem delimitado de 0,6 cm no aspecto posterior do terço médio à esquerda, com alta suspeição para neoplasia (baixo sinal em T2, moderada/acentuada restrição à difusão e leve hipervascularização), sem significativo contato com a cápsula.

Cápsula prostática: sem abaulamentos ou irregularidades.

Vesículas seminais: simétricas, com morfologia e sinal normais.

Linfonodos: não caracterizamos linfonodomegalias.

Pelve óssea: ausência de lesões ósseas com características suspeitas para lesão secundária.

Bexiga: repleção parcial e conteúdo líquido homogêneo.

Achados adicionais: múltiplos divertículos cólicos, sem sinais inflamatórios.

CONCLUSÃO: Reavaliação por RM de paciente em protocolo de vigilância ativa, caracterizando-se nódulo com alta suspeição para neoplasia clinicamente significante no aspecto posterior do terço médio da zona periférica prostática esquerda, medindo 0,6 cm. Este nódulo já era evidente no estudo prévio de 24/11/2014, porém está mais conspícuo e tem maior grau de restrição à difusão no exame atual (0,77 mm^2/s, ante 0,85 mm^2/s no exame prévio), inferindo maior agressividade. Em uma eventual nova biópsia, recomendamos amostragem direcionada a este nódulo.

Próstata, vesículas seminais direita e esquerda e cotos de ductos deferentes direito e esquerdo, ressecção cirúrgica

Microscopia e Conclusões
Diagnósticas

Adenocarcinoma da próstata, com as seguintes características:
Tamanho: 1,5 x 0,8 cm (maior área estimada à microscopia)
Percentual de parênquima prostático comprometido pela neoplasia: 20%
Tipo histológico: acinar-usual
Grau 7 (4+3) de Gleason (60% em padrão 4; 40% em padrão 3)
Não detectado componente terciário de Gleason (0%)
Localização: predominantemente em regiões apical, média e basal do lobo esquerdo (comprometendo quadrante posterior) e regiões focais na zona periférica dos quadrantes anterior esquerdo e posterior direito
Multifocalidade: presente
Nódulo dominante: não detectado
Infiltração neoplásica perineural: presente
Invasão vascular: não detectada
Presença de extensão neoplásica extraprostática na região posterior do lobo esquerdo, junto à vesícula seminal esquerda, inclusive comprometendo sua parede
Colo vesical: livre de neoplasia
Margem circunferencial do lobo direito: livre
Margem circunferencial do lobo esquerdo: livre
Margem apical (margem uretral): livre
Margem do colo vesical (margem proximal): livre
Uretra prostática livre de neoplasia
Outros achados:
Neoplasia intra-epitelial prostática (PIN) de alto grau.
Hiperplasia nodular da próstata.

Vesícula seminal direita livre de neoplasia.

Segmentos de ductos deferentes direito e esquerdo livres de neoplasia.

Estadiamento anatomopatológico (AJCC, 2010): pT3b.

RMmp na vigilância ativa

Original Paper

Urologia Internationalis

Urol Int
DOI: 10.1159/000444197

Received: October 6, 2015
Accepted after revision: January 21, 2016
Published online: April 6, 2016

Role of Multi-Parametric Magnetic Resonance Image and PIRADS Score in Patients with Prostate Cancer Eligible for Active Surveillance According PRIAS Criteria

Gilberto Laurino Almeida[a, d, e] Giuseppe Petralia[b] Matteo Ferro[a]
Carmen Austrália Paredes Marcondes Ribas[b] Serena Detti[a]
Barbara Alicja Jereczek-Fossa[a, c] Deliu Victor Matei[a] Ioan Coman[f]
Ottavio De Cobelli[a, c, f]

73 pacientes com critérios de VA, operados

Sensibilidade RMmp para detectar upstaging 92%, upgrading 76% e doença desfavorável 76%

ALBERT EINSTEIN
HOSPITAL ISRAELITA

Crescimento RM Próstata 2008 a 2018

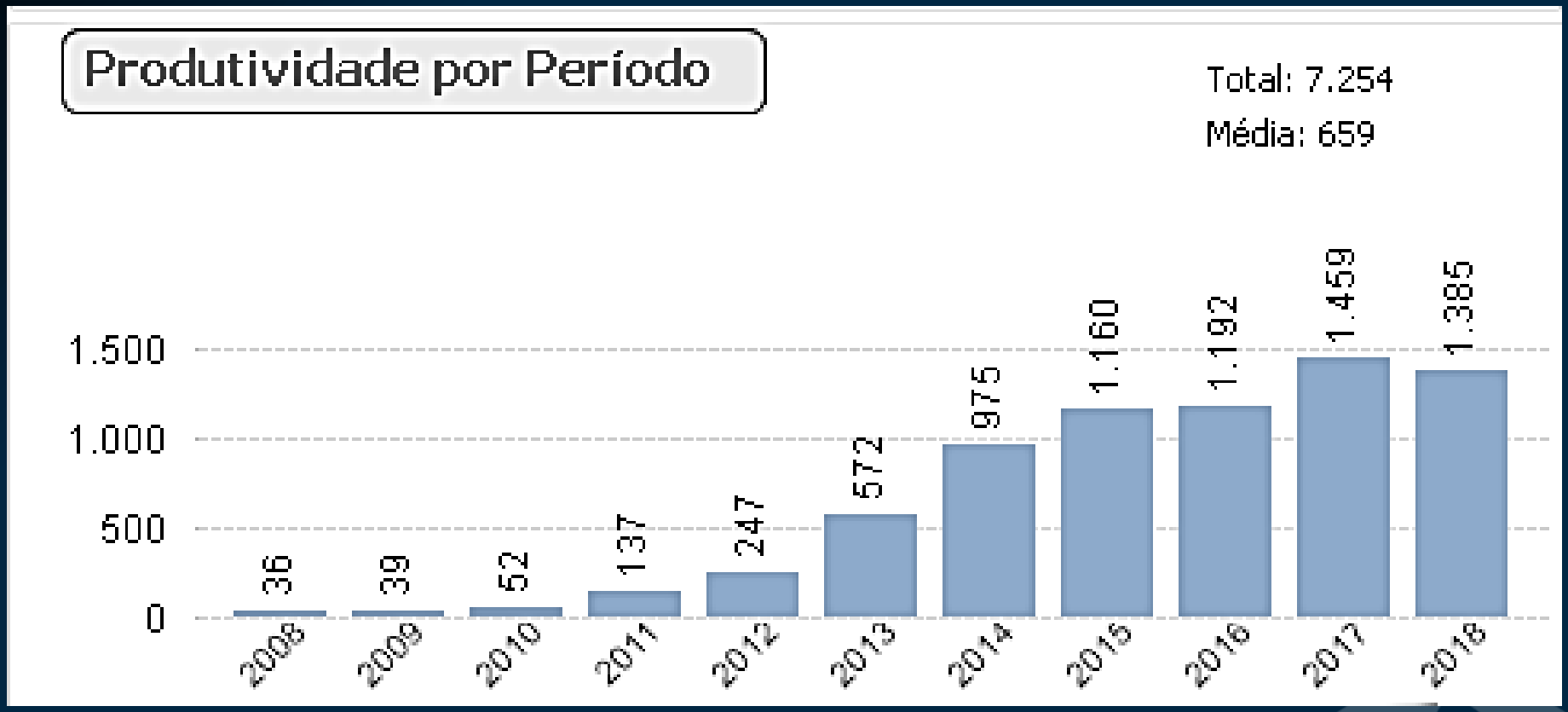

Em 10 anos crescimento de 3747%

Custo / reembolso da RMmp no Brasil

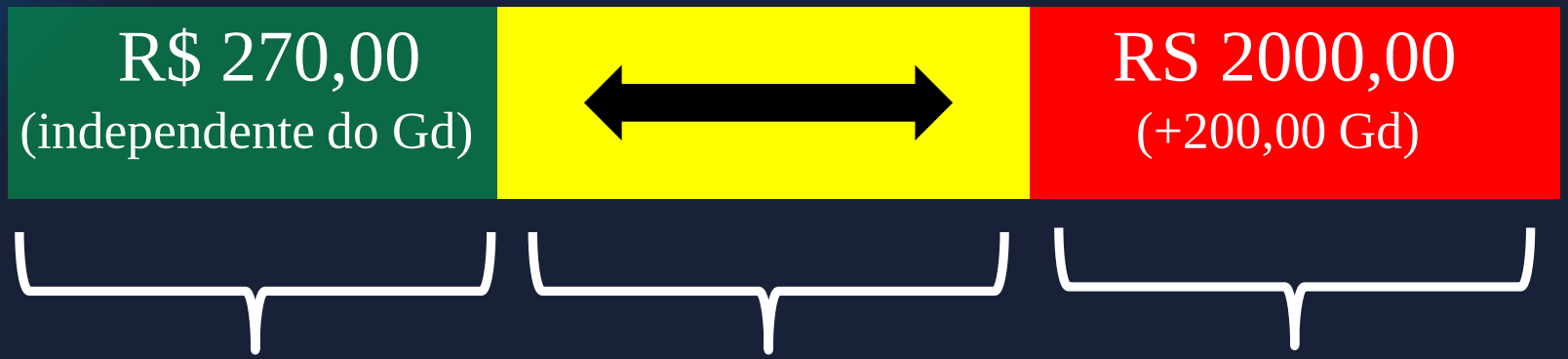

Are Dynamic Contrast-Enhanced Images Necessary for Prostate Cancer Detection on Multiparametric Magnetic Resonance Imaging?

Thaís Caldara Mussi,[1] Tatiana Martins,[1,2] Rodrigo Gobbo Garcia,[3] Renee Zon Filippi,[4] Gustavo Caserta Lemos,[5] Ronaldo Hueb Baroni[1]

AV	Contrast	Sensitivity	Specificity	PPV	NPV	Accuracy
Reader 1	With	63.0 (54.8-71.3)	77.1 (72.3-81.9)	38.8 (30.0-47.5)	88.0 (83.9-92.1)	73.0 (68.8-77.3)
	Without	63.7 (54.5-72.9)	75.9 (71.2-80.6)	36.5 (28.0-45.0)	88.1 (84.0-92.2)	72.2 (68.0-76.4)
	p-value	0.837	0.551	0.084	0.752	0.599
	N	274	1142	448	968	1416
Reader 2	With	80.7 (73.9-87.6)	57.1 (51.8-62.4)	30.7 (23.4-38.0)	91.3 (87.7-94.9)	60.6 (55.8-65.4)
	Without	74.0 (65.3-82.7)	65.5 (60.1-71.0)	29.9 (22.7-37.2)	89.8 (86.0-93.6)	66.1 (61.4-70.9)
	p-value	0.052	**0.004**	0.494	0.109	**0.024**
	n	271	1139	660	750	1410

Clinical Genitourinary Cancer, *PII: S1558-7673* © 2016 Elsevier Inc. All rights reserved.
Keywords: Dynamic-contrast enhanced, Magnetic resonance imaging, Prostate cancer, Prostatic neoplasms

Brazil MR Installed Base Forecast

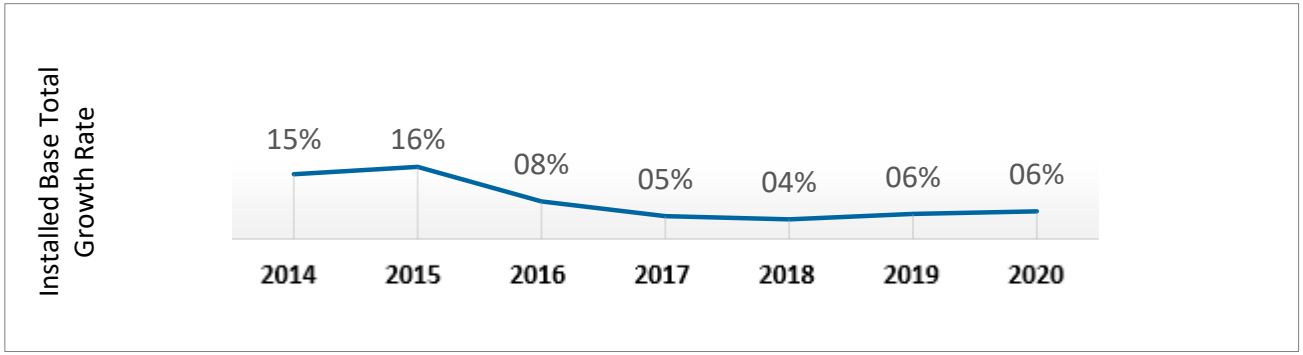

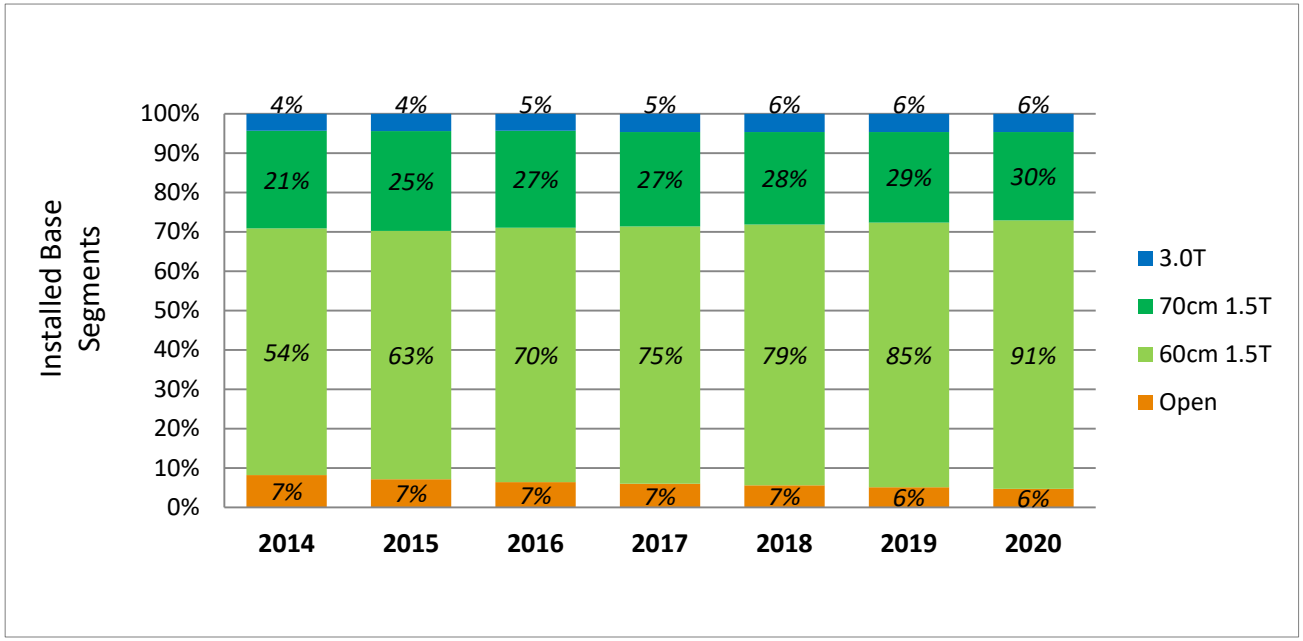

Source: COCIR

RM biparamétrica: o futuro do rastreamento por imagem??

BJU Int 2015; **115**: 381–388

BJUI
BJU International

Diagnostic value of biparametric magnetic resonance imaging (MRI) as an adjunct to prostate-specific antigen (PSA)-based detection of prostate cancer in men without prior biopsies

Soroush Rais-Bahrami*, M. Minhaj Siddiqui*, Srinivas Vourganti*, Baris Turkbey†, Ardeshir R. Rastinehad*, Lambros Stamatakis*, Hong Truong*, Annerleim Walton-Diaz*, Anthony N. Hoang*, Jeffrey W. Nix*, Maria J. Merino‡, Bradford J. Wood§, Richard M. Simon¶, Peter L. Choyke† and Peter A. Pinto*‡

*Urologic Oncology Branch, †Molecular Imaging Program, ‡Laboratory of Pathology, §Center for Interventional Oncology, and ¶Biometric Research Branch, National Cancer Institute, National Institutes of Health, Bethesda, MD, USA

lesions (SPL) on B-MRI. B-MRI performed well for the detection of prostate cancer with an area under the curve (AUC) of 0.80 (compared with 0.66 and 0.74 for PSA level and PSAD, respectively). We derived combined PSA and

Combined Biparametric Prostate Magnetic Resonance Imaging and Prostate-specific Antigen in the Detection of Prostate Cancer: A Validation Study in a Biopsy-naive Patient Population

Michele Fascelli, Soroush Rais-Bahrami, Sandeep Sankineni, Anna M. Brown, Arvin K. George, Richard Ho, Thomas Frye, Amichai Kilchevsky, Raju Chelluri, Steven Abboud, M. Minhaj Siddiqui, Maria J. Merino, Bradford J. Wood, Peter L. Choyke, Peter A. Pinto, and Baris Turkbey

UROLOGY 88: 125–134, 2016.

Screen positive lesions on B-MRI had the highest sensitivity (95.5%) and negative predictive value of 71.4% compared with PSA and PSAD. B-MRI significantly improved sensitivity (43.2-72.7%, $P = .0002$) when combined with PSAD. The negative predictive value of PSA increased with B-MRI, achieving 91.7% for B-MRI and PSA for Gleason ≥3 + 4. Overall accuracies of the composite equations were 81.4% (B-MRI and PSA) and 78.0% (B-MRI and PSAD).

Research

Biparametric versus multiparametric MRI in the diagnosis of prostate cancer

Karen Cecilie Duus Thestrup[1], Vibeke Logager[1], Ingerd Baslev[2], Jakob M Møller[1], Rasmus Hvass Hansen[1] and Henrik S Thomsen[1]

Acta Radiologica Open
5(8) 1–8
© The Foundation Acta Radiologica 2016
Reprints and permissions:
sagepub.co.uk/journalsPermissions.nav
DOI: 10.1177/2058460116663046
arr.sagepub.com
SAGE

Table 4. The detection rates of Readers 1 and 2.

	Reader 1		Reader 2	
	bp-MRI	mp-MRI	bp-MRI	mp-MRI
Sensitivity	0.94	1.0	0.96	0.93
Specificity	0.15	0.04	0.15	0.16
PPV	0.36	0.34	0.36	0.36
NPV	0.83	1.00	0.87	0.81

Christiane K. Ku
Robin Bruhn, MI
Nils Krämer, MD
Sven Nebelung,
Axel Heidenreicl
Simone Schradi

Table 4

Comparison of Diagnostic Accuracy of the Abbreviated Biparametric versus the Full Multiparametric Protocol

542 men,

Parameter	Abbreviated Biparametric Protocol	Full Multiparametric Protocol
For diagnosis of any prostate cancer ($n = 180$)		
True-positive diagnosis	154	156
False-negative diagnosis	26	24
True-negative diagnosis	329	319
False-positive diagnosis	33	43
Sensitivity (%)*	85.6 (79.6, 90.3)	86.7 (80.8, 91.3)
Specificity (%)*	90.9 (87.4, 93.6)	88.1 (84.3, 91.3)
Positive predictive value*	82.4 (76.1, 87.5)	78.4 (72.0, 83.90
Negative predictive value*	92.7 (89.5, 95.2)	93.0 (89.8, 95.5)
Overall diagnostic accuracy*	89.1 (86.2, 91.6)	87.6 (84.6, 90.3)
For diagnosis of significant prostate cancer ($n = 147$)†		
True-positive diagnosis‡	138	139
False-negative diagnosis‡	9	8
True-negative diagnosis‡	346	335
False-positive diagnosis‡	49	60
Sensitivity (%)*	93.9 (88.7, 97.2)	94.6 (88.8, 97.2)
Specificity (%)*	87.6 (83.9, 90.7)	84.8 (80.1, 88.2)
Positive predictive value (%)*	73.8 (66.9, 79.9)	69.8 (63.0, 76.1)
Negative predictive value (%)*	97.5 (95.2, 98.8)	97.7 (95.5, 99.0)
Overall diagnostic accuracy (%)*	89.3 (86.4, 91.8)	87.5 (84.4, 90.1)

* Data in parentheses are 95% CIs.

† Significant prostate cancer was defined as intermediate- and high-risk prostate cancers. Intermediate-risk cancers were defined as PSA between 10 and 20 ng/mL, Gleason score of 7, and clinical stage T2b. High-risk cancers were PSA greater than 20 ng/mL, and/or a Gleason score greater than or equal to 8, or clinical stage T2c-T3a.

‡ Diagnosis of insignificant prostate cancer considered as false-positive diagnosis.

Radiology

Cost-effectiveness of MR Imaging–guided Strategies for Detection of Prostate Cancer in Biopsy-Naive Men[1]

Shivani Pahwa, MD
Nicholas K. Schiltz, PhD
Lee E. Ponsky, MD
Ziang Lu, BA
Mark A. Griswold, PhD
Vikas Gulani, MD, PhD

Purpose: To evaluate the cost-effectiveness of multiparametric diagnostic magnetic resonance (MR) imaging examination followed by MR imaging–guided biopsy strategies in the detection of prostate cancer in biopsy-naive men presenting with clinical suspicion of cancer for the first time.

Results: Noncontrast MR imaging followed by cognitively guided MR biopsy (no standard biopsy if MR imaging findings were negative) was the most cost-effective approach, yielding an additional NHB of 0.198 QALY compared with the standard biopsy approach. Noncontrast MR imaging followed by in-gantry MR imaging–guided biopsy (no standard biopsy if MR imaging findings were negative) led to the highest NHB gain of 0.251 additional QALY compared with the standard biopsy strategy. All MR imaging strategies were cost-effective in 94.05% of Monte Carlo simulations. Analysis by age groups yielded similar results.

[1] From the Departments of Radiology (S.P., M.A.G., V.G.) and Urology (L.E.P.), University Hospitals Case Medical Center, 11100 Euclid Ave, Bolwell B120, Cleveland, OH 44106-0500; Department of Epidemiology and Biostatistics (N.K.S.) and Department of Biomedical Engineering (M.A.G., V.G.), Case Western Reserve University, Cleveland, Ohio; and Case Western Reserve University School of Medicine, Cleveland, Ohio (Z.L.). Received September 18, 2016; revision requested November 15; revision received January 22, 2017; accepted February 7; final version accepted February 24. **Address correspondence to** V.G. (e-mail:

Conclusão

- RMmp é o exame de escolha para detecção tumoral
  - RMmp como rastreamento tumoral
  - Não biopsiar em PR 1 e 2, conduta individualizada em PR 3, biopsiar com fusão de imagens em PR 4 e 5
- RMmp sempre foi exame de escolha para estadiamento local
- RMmp deverá ser incorporada aos protocolos de vigilância ativa
- O exame de RMmp terá de se tornar mais rápido, barato, acessível e inócuo
  - **RMmp em aparelho 3T se possível, RMbp em aparelho 1,5T se única opção viável**

ALBERT EINSTEIN
HOSPITAL ISRAELITA

X CONGRESSO INTERNACIONAL DE
UROONCOLOGIA
V SIMPÓSIO MULTIPROFISSIONAL DE URO-ONCOLOGIA
4 a 6 de abril de 2019 | SHERATON WTC | GOLDEN HALL

Obrigado!!!!

Ronaldo Hueb Baroni