Existe papel para o PET com PSMA no estadiamento do câncer de próstata?

Marcelo Queiroz

23/11/2018

I ADVANCED PROSTATE CANCER CONSENSUS FOR DEVELOPING COUNTRIES

II SIMPÓSIO INTERNACIONAL

GU - REVIEW 2018 - LACOG

HOSPITAL SÍRIO-LIBANÊS

MEDICINA USP

Por que PSMA como traçador?

- PSMA (antígeno **específico** de membrana prostática)
  - 100-1.000x mais expresso no CaP que em outros tecidos
  - Traçador com maior especificidade em lesões de natureza prostática

- **Outros traçadores:**
  - **Colina**
  - **Bombesina**
  - Acetato
  - Metionina
  - FDG

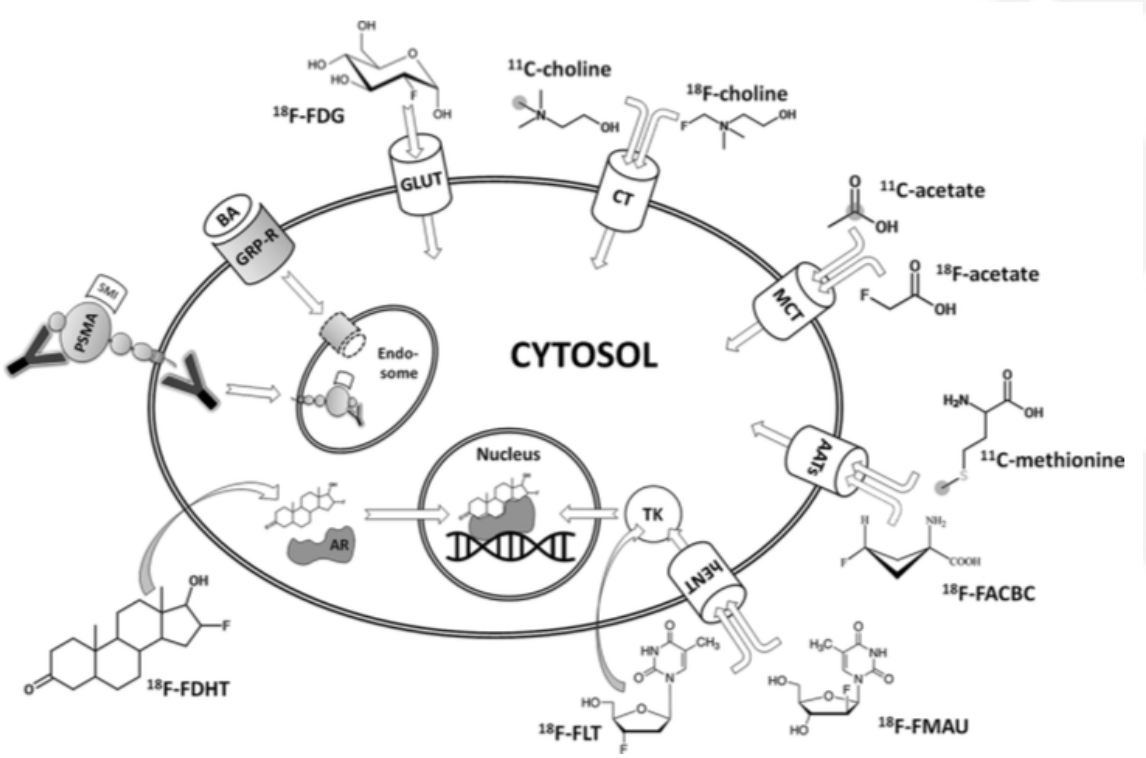

Wibmen A.G. et al, Radiographics, 2016

Agenda

- Estadiamento local (T)
- Estadiamento regional (N)
- Estadiamento sistêmico (M)
- Planejamento terapêutico
  - Cirurgia
  - Radioterapia
- Impacto clínico
- Perspectivas

Agenda

- Estadiamento local (T)
- Estadiamento regional (N)
- Estadiamento sistêmico (M)
- Planejamento terapêutico
  - Cirurgia
  - Radioterapia
- Impacto clínico
- Perspectivas

Estadiamento local (T)

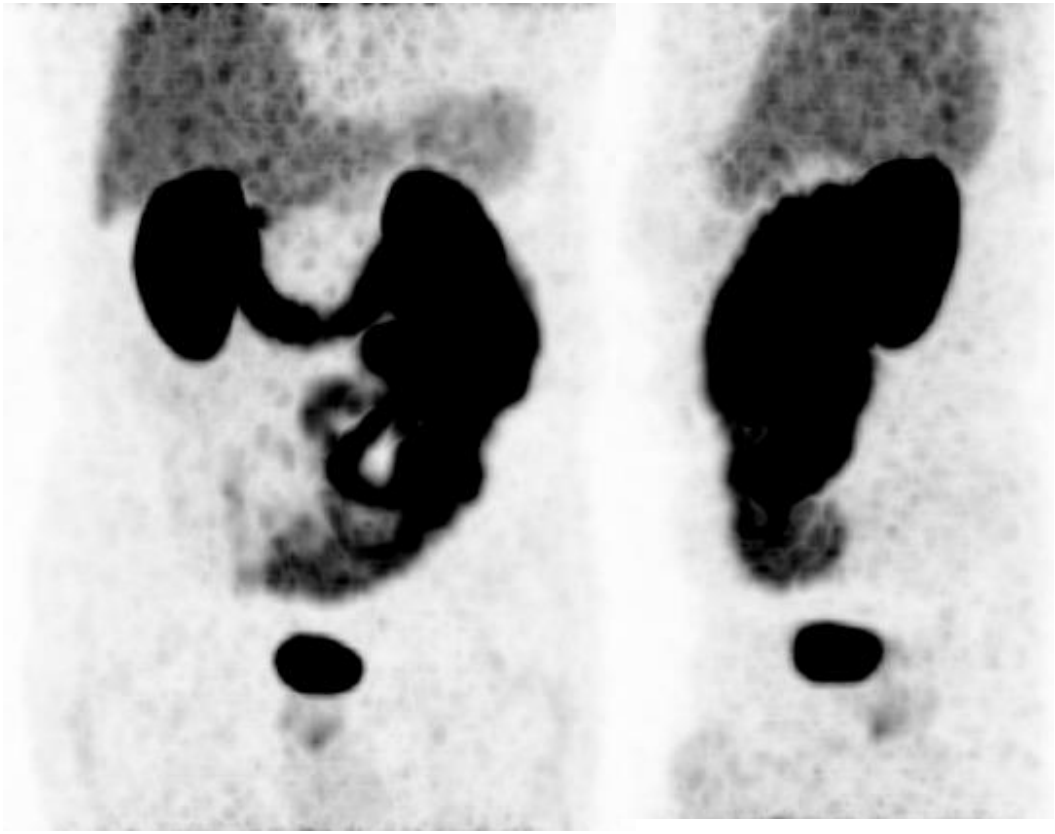

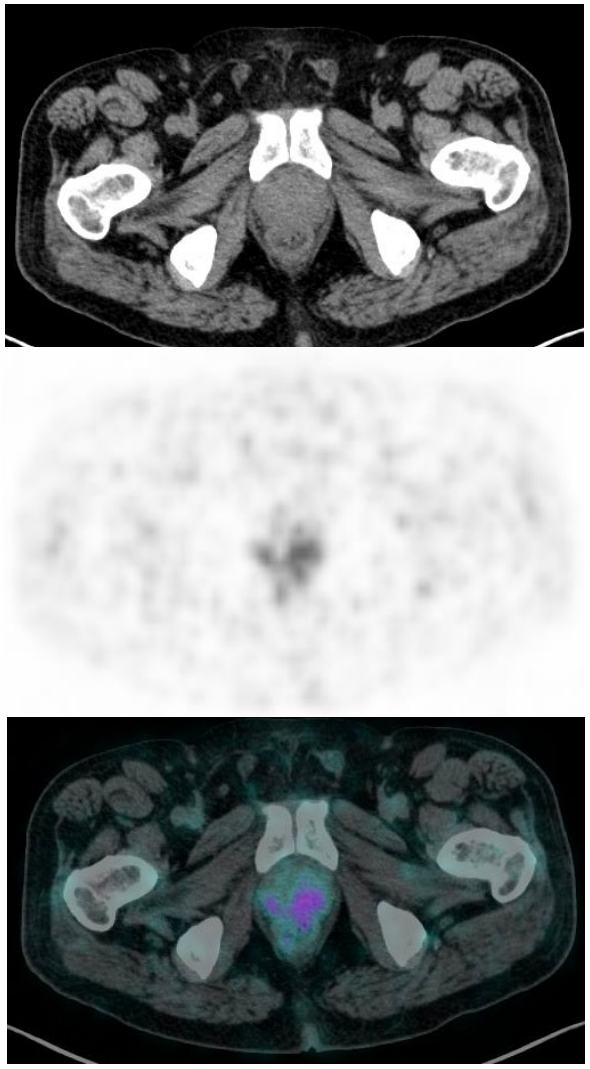

Gleason 7a (3+4) em 2 de 16 fragmentos

Estadiamento local (T)

Após prostatectomia, Gleason 9 (Esquerda) e Gleason 7 (Direita)

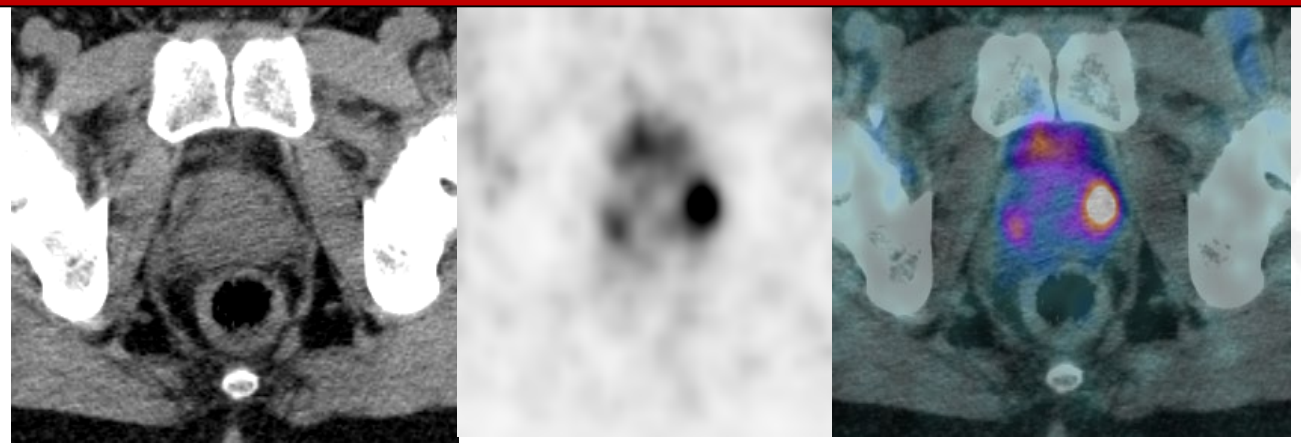

67 anos, com diagnóstico de tumor Gleason 7(4+3), de alto risco (PSA 61,8 ng/mL)

Estadiamento local (T)



Após prostatectomia, Gleason 9 (4+5)

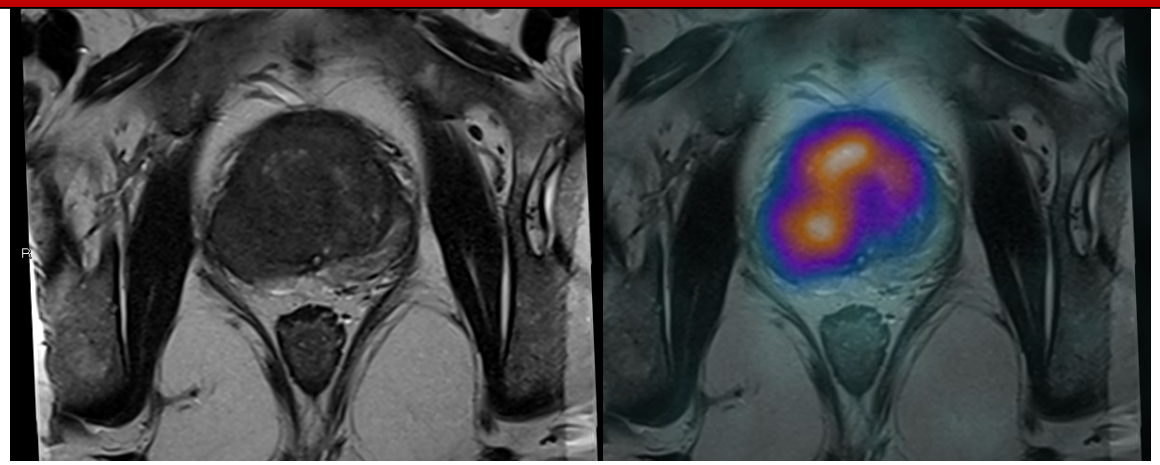

72 anos, com diagnóstico de tumor Gleason 7b (4+3) e PSA = 9,0 ng/ml

Estadiamento local (T)

- PET com localização correta do tumor em **92,9%**

Badäus L, Eur Urology 2015
Maurer T. et al, The Journal Urol 2015

- PSMA positivo em 93% tumor primário
  - GS 8-10 e PSA>10 → correlação com SUVmax mais elevados (>17)

C. Uprimny et al. – Eur J Nucl Med Mol Imaging. 2017

- Estadiamento de médio e alto risco → 100% positividade no tumor primário

Beheshti et al. – EANM 2016

- Pode haver um incremento de detectabilidade tumoral prostática PSMA + RMmp (*ainda suposição*)

Asim Afaq - Int Urol Nephrol 2017

Agenda

- Estadiamento local (T)
- Estadiamento regional (N)
- Estadiamento sistêmico (M)
- Planejamento terapêutico
  - Cirurgia
  - Radioterapia
- Impacto clínico
- Perspectivas

Estadiamento regional (N)

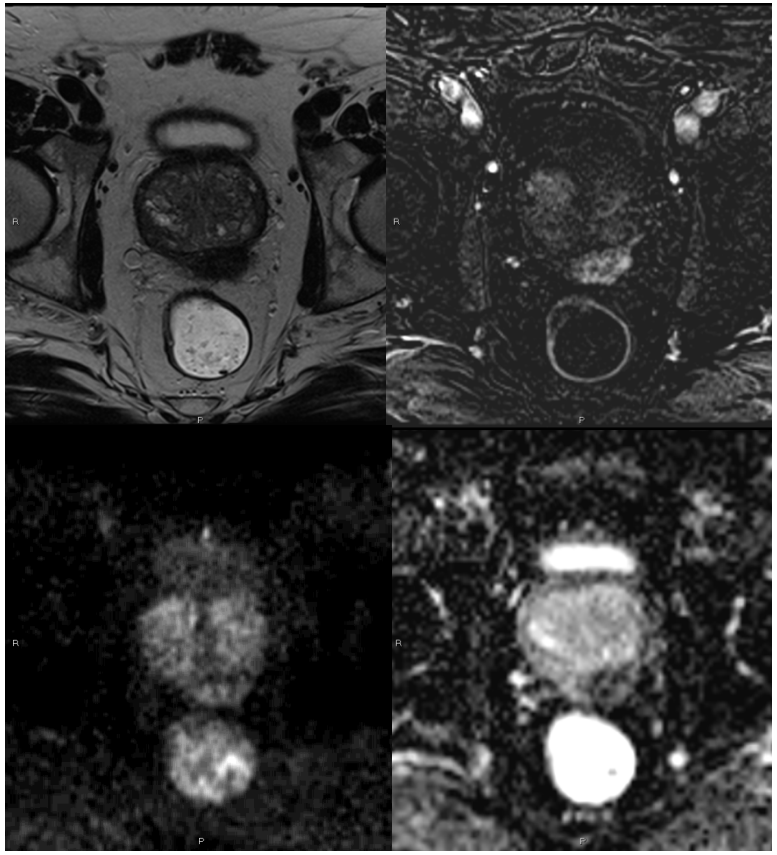

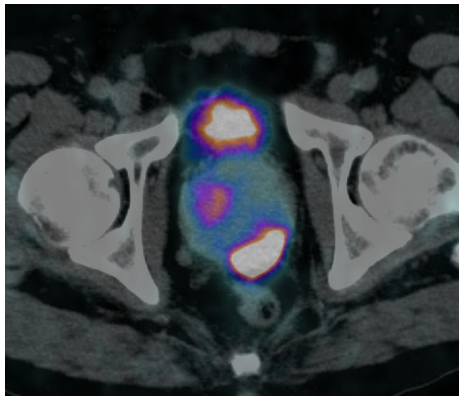

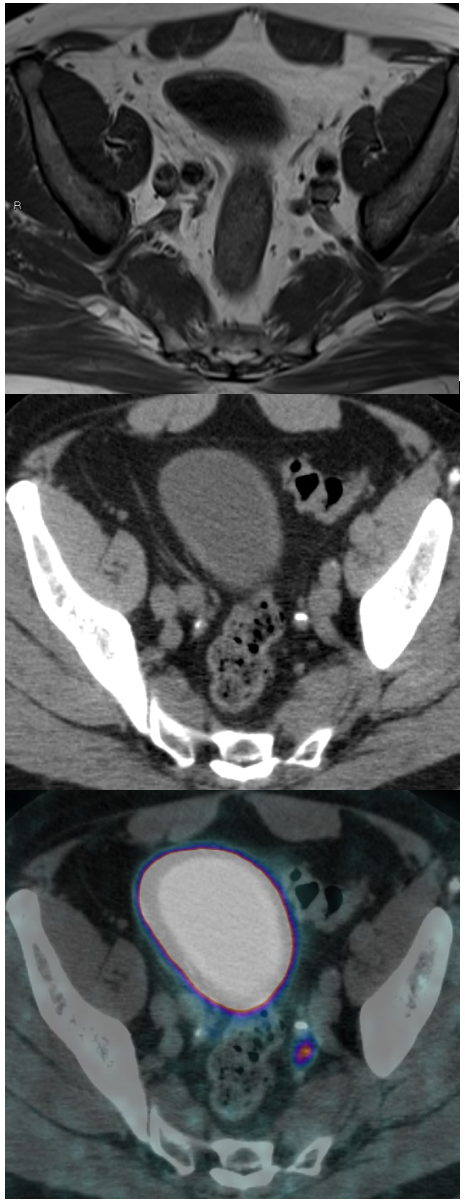

67 anos, adenocarcinoma de próstata Gleason 8 e PSA = 15 ng/ml

Estadiamento regional (N)

DIAGNÓSTICO: Produto de prostatectomia radical com ressecção em bloco de próstata, vesículas seminais bilaterais e margens prostáticas:

1. Próstata: Adenocarcinoma grau 9(4+5) de Gleason (Grau 5 ISUP).
O tumor tem padrão acinar usual.
Compromete 57% do volume glandular, correspondendo a 25,7 cc.
A neoplasia é bilateral, multifocal, mas infiltra predominantemente o lobo esquerdo.
Extensa embolização neoplásica intravascular.
Extensa infiltração do tecido extraprostático em toda a extensão do lobo esquerdo.
Margens cirúrgicas radiais livres de neoplasia.

2. Margens cirúrgicas ao nível do colo vesical: Ausência de neoplasia.

3. Margens cirúrgicas ao nível do ápice prostático: Ausência de neoplasia.

4. Vesícula seminal direita: Vesícula seminal e ductos ejaculatórios sem alterações relevantes. Ausência de invasão tumoral.

5. Vesícula seminal esquerda: Vesícula seminal e ductos ejaculatórios sem alterações relevantes. Ausência de invasão tumoral.

6. Linfonodos obturadores direitos: Adenocarcinoma metastático em 1 de 4 linfonodos dissecados. A lesão tem 7 mm e não compromete a cápsula ou o tecido adiposo perinodal (1/4).

7. Linfonodos ilíacos internos direitos: Linfadenite reacional inespecífica. Infiltração gordurosa. Ausência de neoplasia metastática (0/3).

8. Linfonodos ilíacos externos direitos: Linfadenite reacional inespecífica. Infiltração gordurosa. Ausência de neoplasia metastática (0/4).

9. Linfonodos obturadores esquerdos: Linfadenite reacional inespecífica. Infiltração gordurosa. Ausência de neoplasia metastática (0/8).

10. Linfonodos ilíacos internos esquerdos: Linfadenite reacional inespecífica. Infiltração gordurosa. Ausência de neoplasia metastática (0/3).

11. Linfonodos ilíacos externos esquerdos: Linfadenite reacional inespecífica. Infiltração gordurosa. Ausência de neoplasia metastática (0/7).

Estadiamento - TNM 2010: pT3aN1

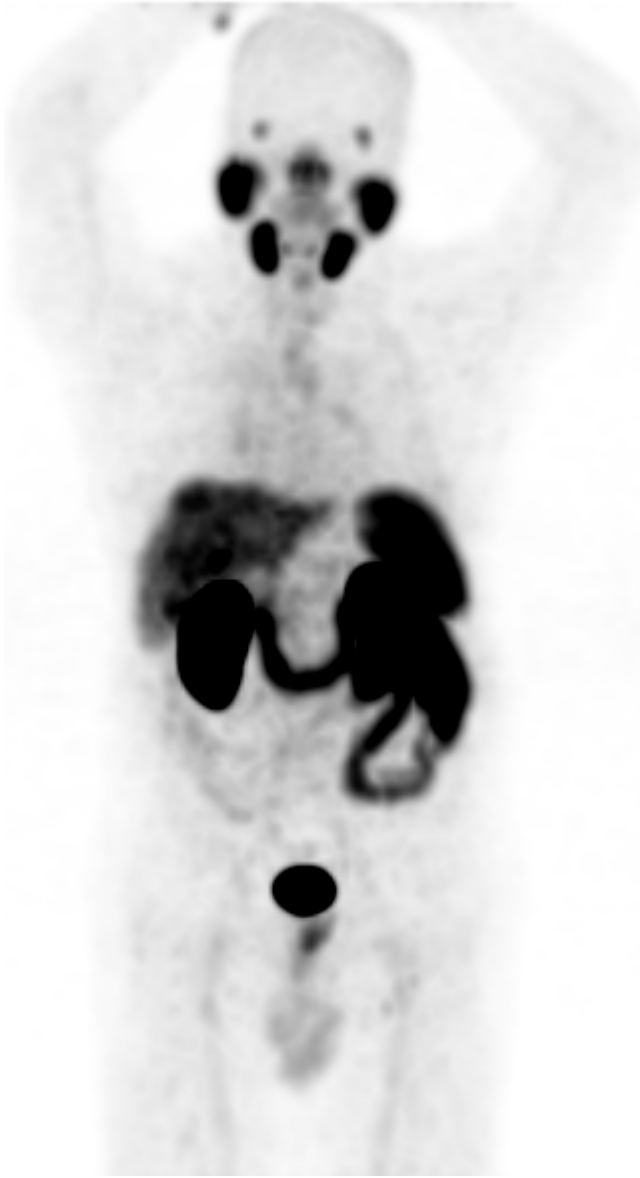

57 anos, adenocarcinoma de próstata Gleason 9 (4+5) e PSA = 42 ng/ml

Estadiamento regional (N)

Table 2 – Histopathologic lymph node characteristics of the total patient population ($n = 30$) stratified by ^{68}Ga-PSMA PET/CT detection of lymph node metastases

	No LN metastases ($n = 18$)			LN metastases ($n = 12$)		
	PSMA negative ($n = 18$)	PSMA positive ($n = 0$)	p	PSMA negative ($n = 8$)	PSMA positive ($n = 4$)	p
LNs removed, no. (%)	393 (64.6)	–	NA	141 (23.2)	74 (12.2)	0.833
LNMs removed, no. (%)	0 (0)	–	NA	19 (35.8)	34 (64.2)	0.808
Intranodal LNM size, mm *, mean, median (range)	–	–	NA	4.5, 4.3 (1.0–10.8)	12.8, 13.6 (4.0–20.0)	0.048
Overall LNM size, mm *, mean, median (range)	–	–	NA	19.4, 20.5 (4.0–40.0)	31.8, 25.5 (12.0–64.0)	0.368

LN = lymph node; LNM = lymph node metastasis; NA = not applicable; PSMA = prostate-specific membrane antigen.
* Largest/index lymph node per patient is presented.

Table 3 – Results of ^{68}Ga-PSMA PET/CT lymph node metastases verified by histopathology after radical prostatectomy and extended pelvic lymph node dissection

	No LN metastases ($n = 18$)	LN metastases ($n = 12$)	
PSMA positive ($n = 4$), n (%)	0 (0)	4 (33.3)	PPV 100%
PSMA negative ($n = 26$), n (%)	18 (100)	8 (66.7)	NPV 69.2%
	Specificity 100%	Sensitivity 33.3%	Accuracy 73.3%

LN = lymph node; NPV = negative predictive value; PPV = positive predictive value; PSMA = prostate-specific membrane antigen.

EUROPEAN UROLOGY 69 (2016) 393–396

Initial Experience of ^{68}Ga-PSMA PET/CT Imaging in High-risk Prostate Cancer Patients Prior to Radical Prostatectomy

Lars Budäus [a,†,], Sami-Ramzi Leyh-Bannurah [a,b,†], Georg Salomon [a], Uwe Michl [a], Hans Heinzer [a], Hartwig Huland [a], Markus Graefen [a], Thomas Steuber [a], Clemens Rosenbaum [a,b]*

[a] *Martini-Clinic Prostate Cancer Center, University Hospital Hamburg-Eppendorf, Hamburg, Germany;*
[b] *Department of Urology, University Hospital Hamburg-Eppendorf, Hamburg, Germany*

Eur J Nucl Med Mol Imaging (2016) 43:1407–1409
DOI 10.1007/s00259-016-3401-x

EDITORIAL COMMENTARY

Can ^{68}GA-PSMA or radiolabeled choline PET/CT guide salvage lymph node dissection in recurrent prostate cancer?

Fabio Zattoni [1,2] · Andrea Gutilla [3] · Laura Evangelista [4]

Estadiamento regional (N)

- **Estadiamento em riscos intermediário e alto**
  - **N=61**
    - 12/61 (30%) → LN metástases positivas no PET e cirurgia
  - **N = 130**
    - Acurácia → 88,5%
    - Falsos negativos 11/130 (8,4%)
      - 2 PET neg primário
      - 9 micrometa (1-3mm)

Beheshti et al., EANM 2016
Maurer T. et al, The Journal Urol 2015

- **Estadiamento de alto risco (N = 431 pts, 25% estadiamento)**
  - Novos LNs → 39%
  - Mudança de conduta → 51% dos casos.

Roach et al; JNM; 2018;59(1):82-88.

Agenda

- Estadiamento local (T)
- Estadiamento regional (N)
- Estadiamento sistêmico (M)
- Planejamento terapêutico
  - Cirurgia
  - Radioterapia
- Impacto clínico
- Perspectivas

Estadiamento sistêmico (M)

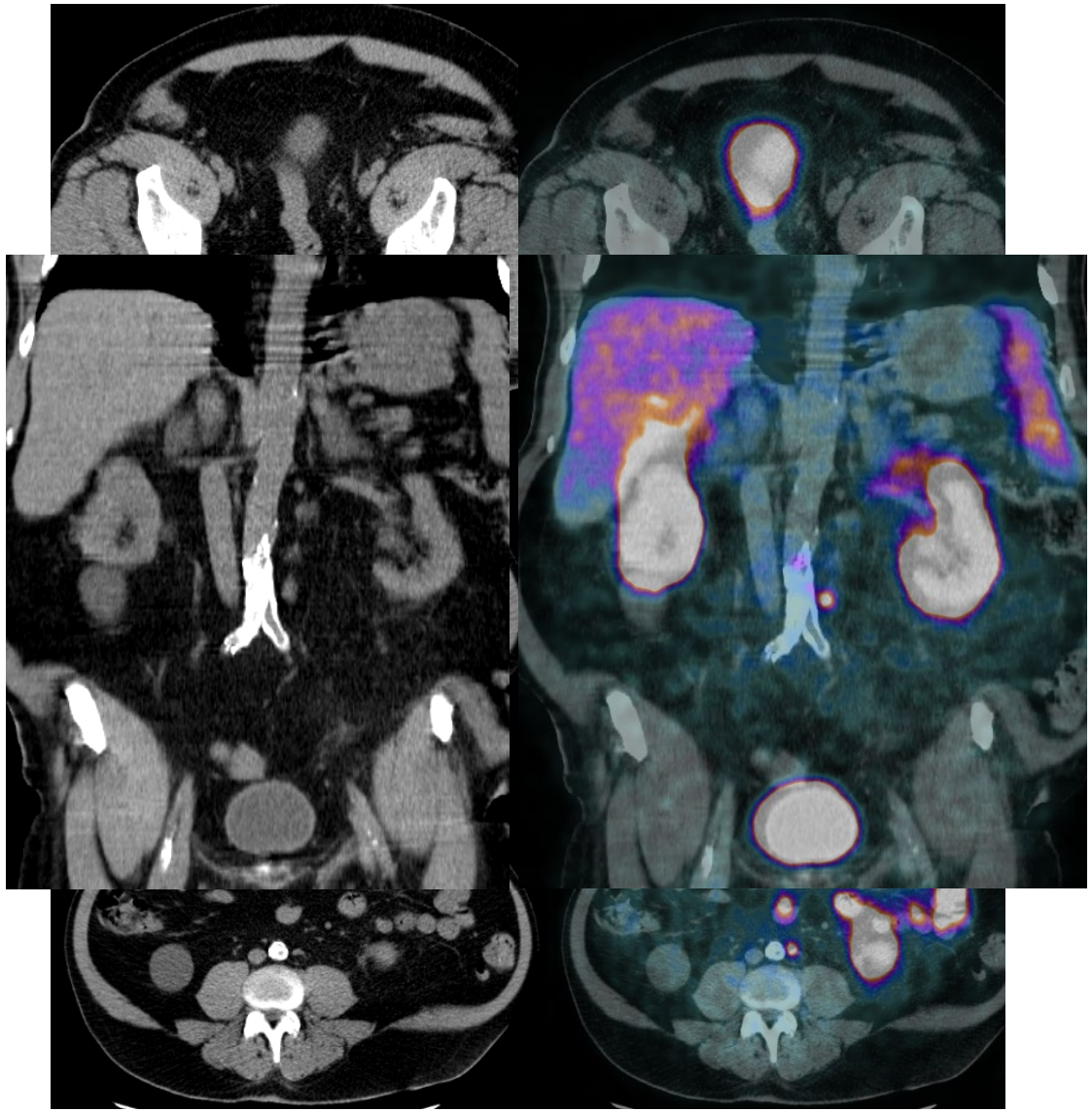

52 anos, adenocarcinoma de próstata Gleason 8 e PSA = 11 ng/ml

Estadiamento sistêmico (M)

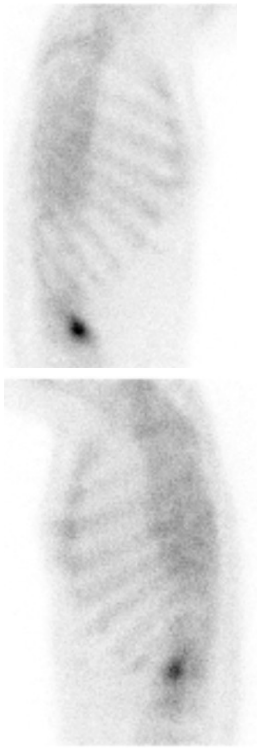

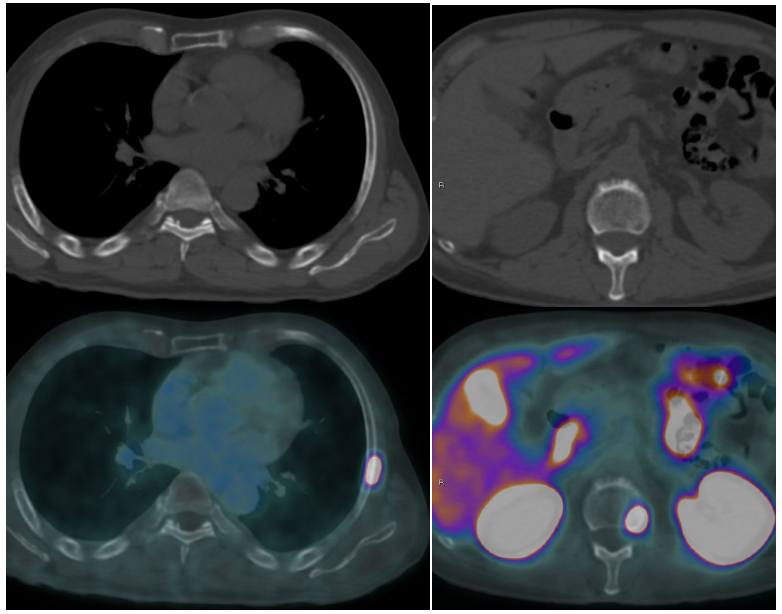

66 anos, adenocarcinoma de próstata Gleason 8 e PSA = 18 ng/ml

Estadiamento sistêmico (M)

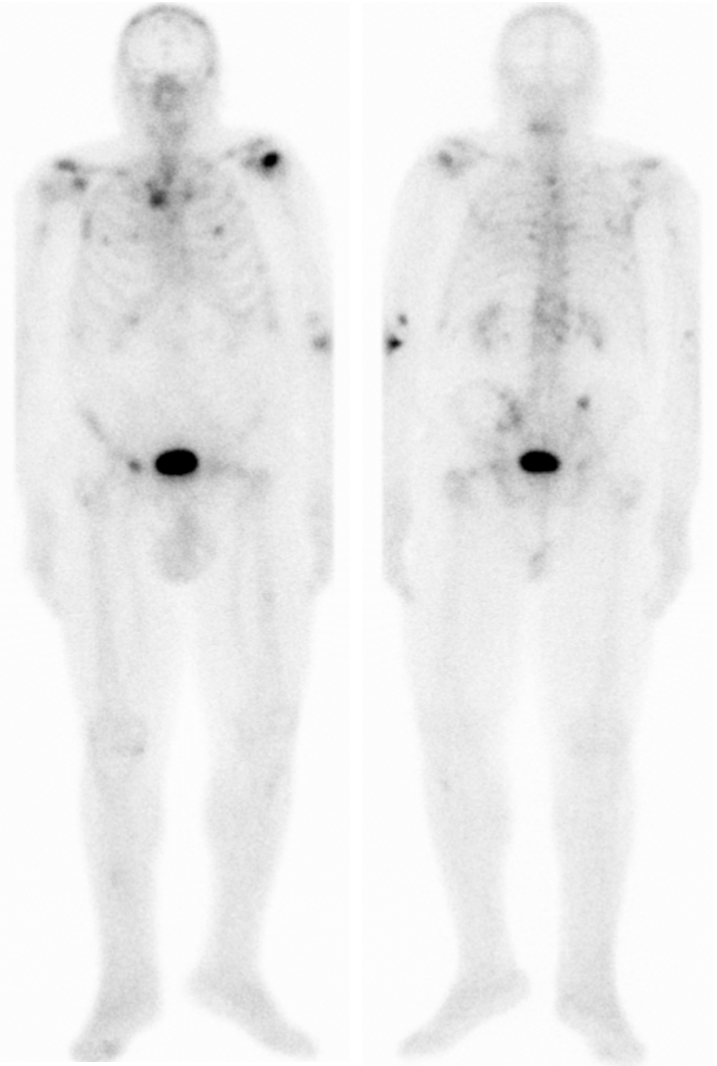

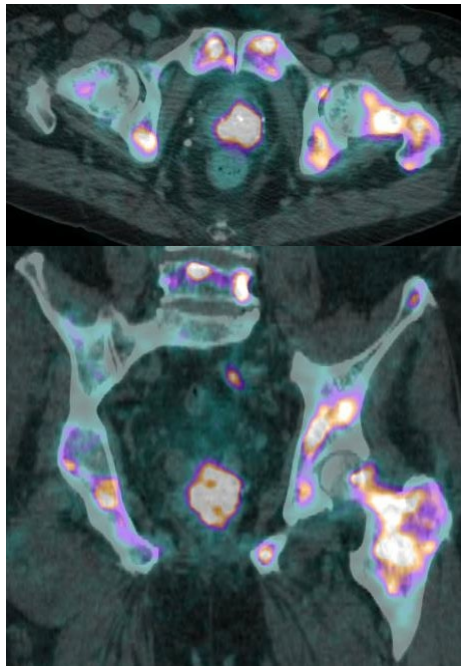

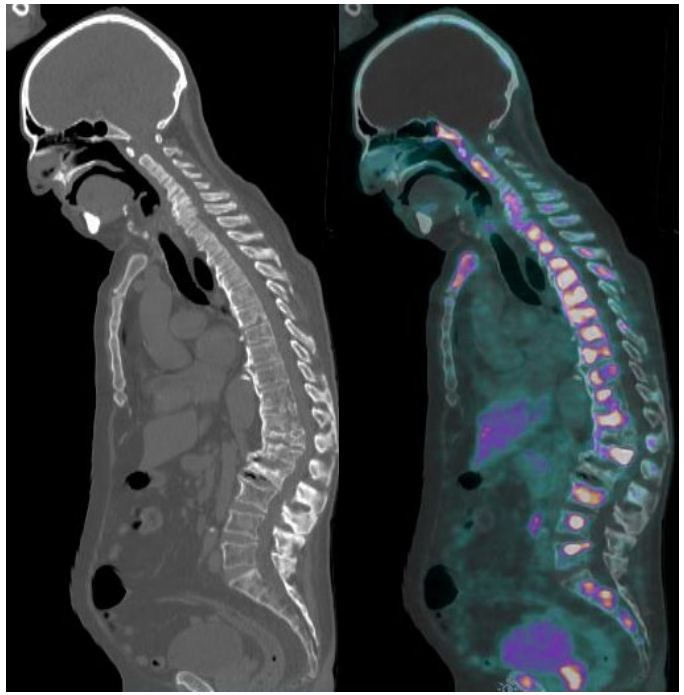

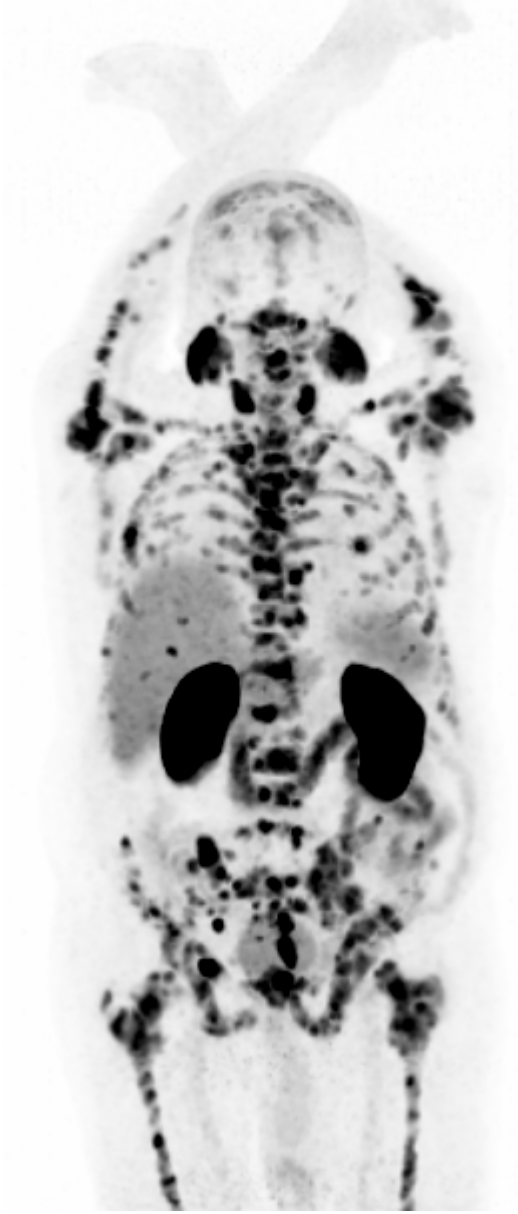

79 anos, adenocarcinoma de próstata Gleason 9 (4+5) e PSA = 5,8 ng/mL

Estadiamento sistêmico (M)

- PET detectou 30% metástase óssea (8/26)
  - **7 em alto risco / 1 em risco intermediário (T2b G7 4+3)**

Freitag et al. - Eur J Nucl Med Mol Imaging 2015

Estadiamento em riscos intermediário e alto (N=61)

- 30% de metástase óssea (18/61)
  - 12 meta óssea exclusiva
  - 6 meta óssea + LN

❖ **PET mudou a conduta em 20% dos pacientes de alto risco**

Beheshti et al. – EANM 2016

Agenda

- Estadiamento local (T)
- Estadiamento regional (N)
- Estadiamento sistêmico (M)
- Planejamento terapêutico
  - Cirurgia
  - Radioterapia
- Impacto clínico
- Perspectivas

Planejamento terapêutico - Cirurgia

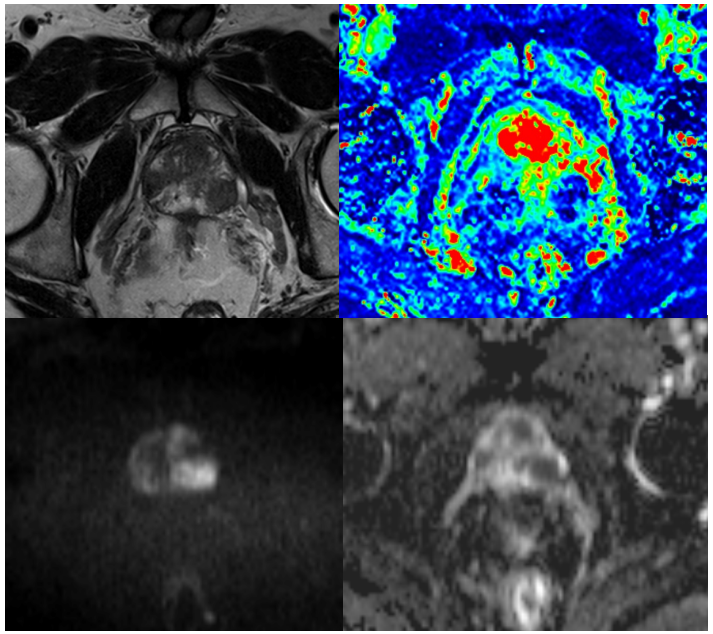

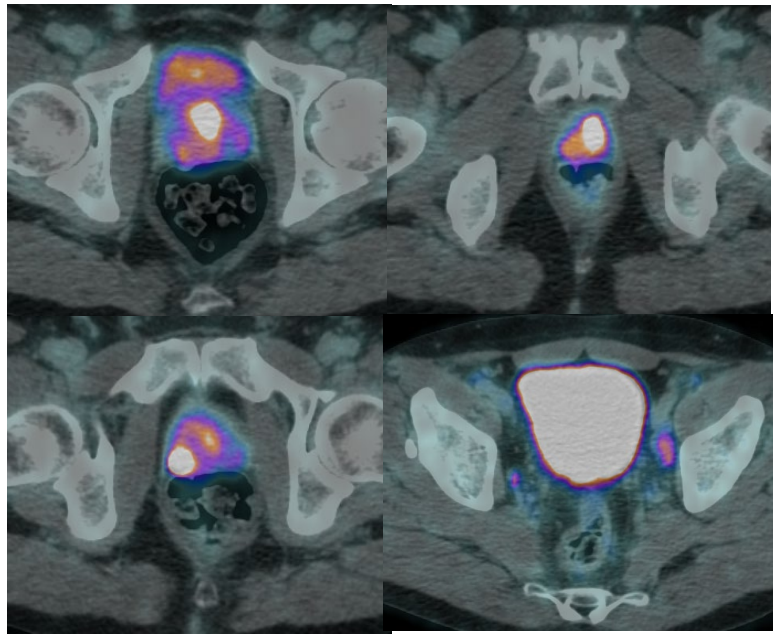

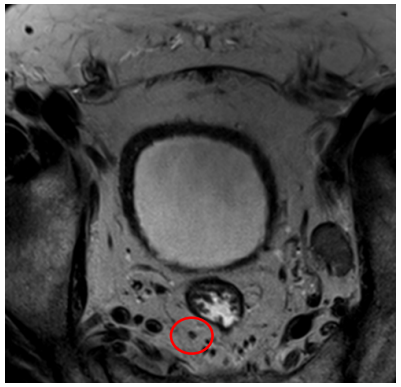

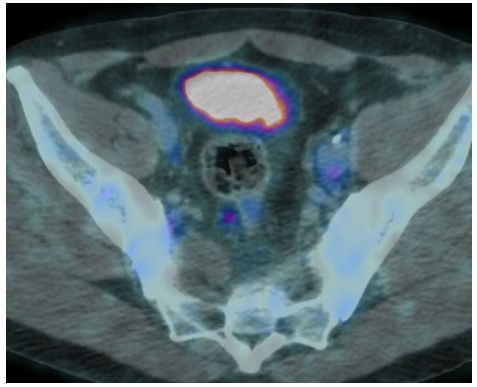

58 anos, adenocarcinoma de próstata Gleason 8 e PSA = 150 ng/ml

Planejamento terapêutico - Cirurgia

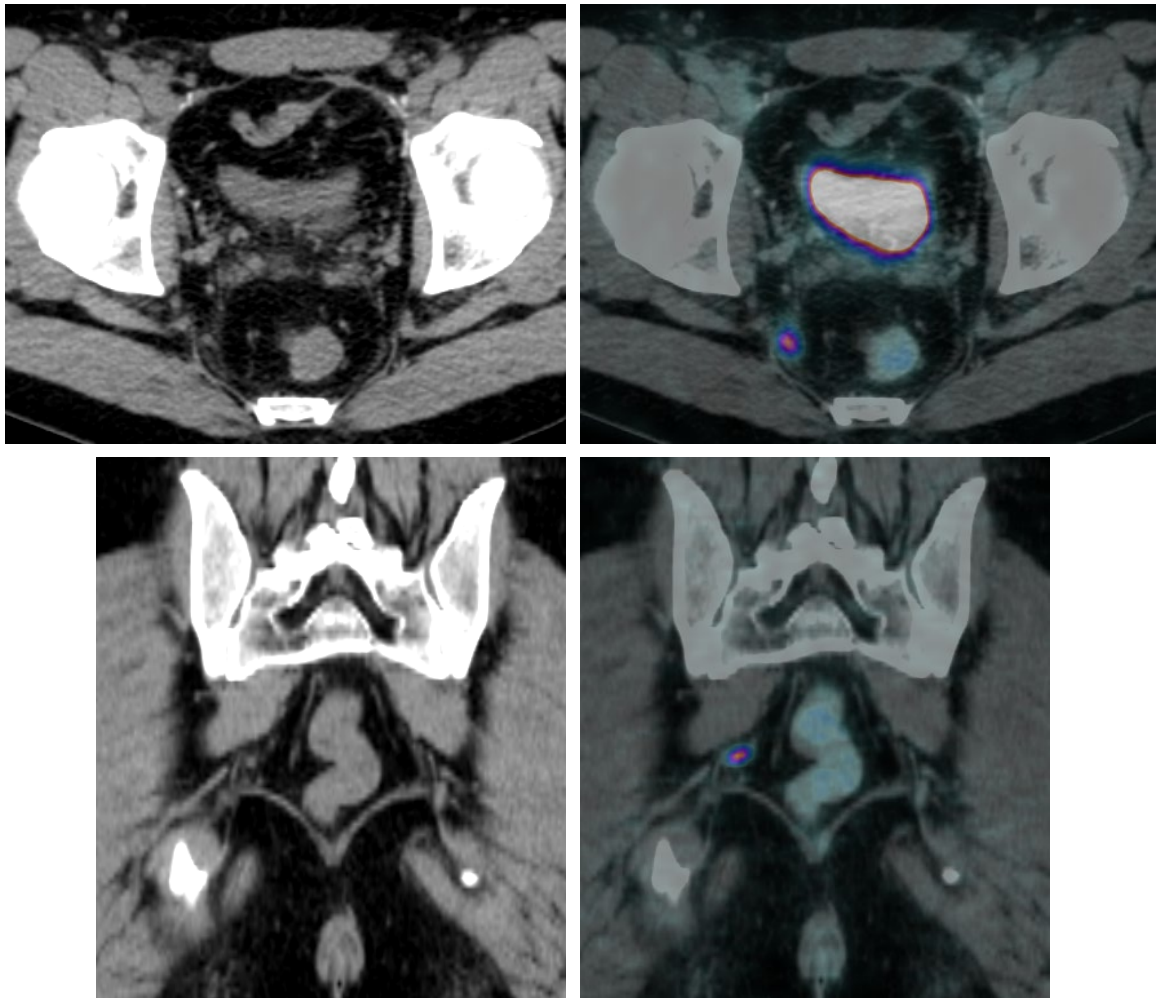

62 anos, PSA = 0,45 ng/mL dois meses após prostatectomia radical (Gleason 8, iPSA = 4,5 ng/mL)

Agenda

- Estadiamento local (T)
- Estadiamento regional (N)
- Estadiamento sistêmico (M)
- Planejamento terapêutico
  - Cirurgia
  - Radioterapia
- Impacto clínico
- Perspectivas

Planejamento terapêutico - Radioterapia

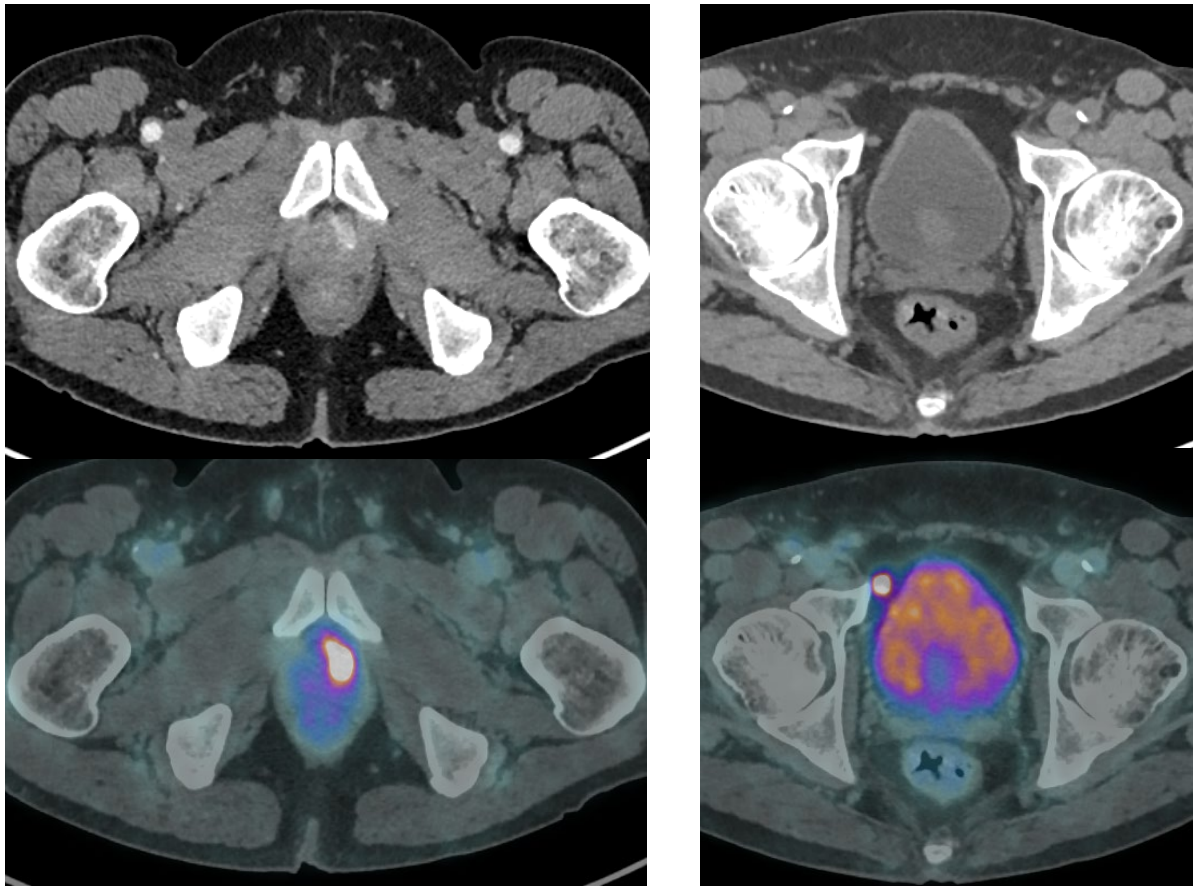

65 anos, adenocarcinoma de próstata Gleason 9 e PSA = 10 ng/ml

Planejamento terapêutico - Radioterapia

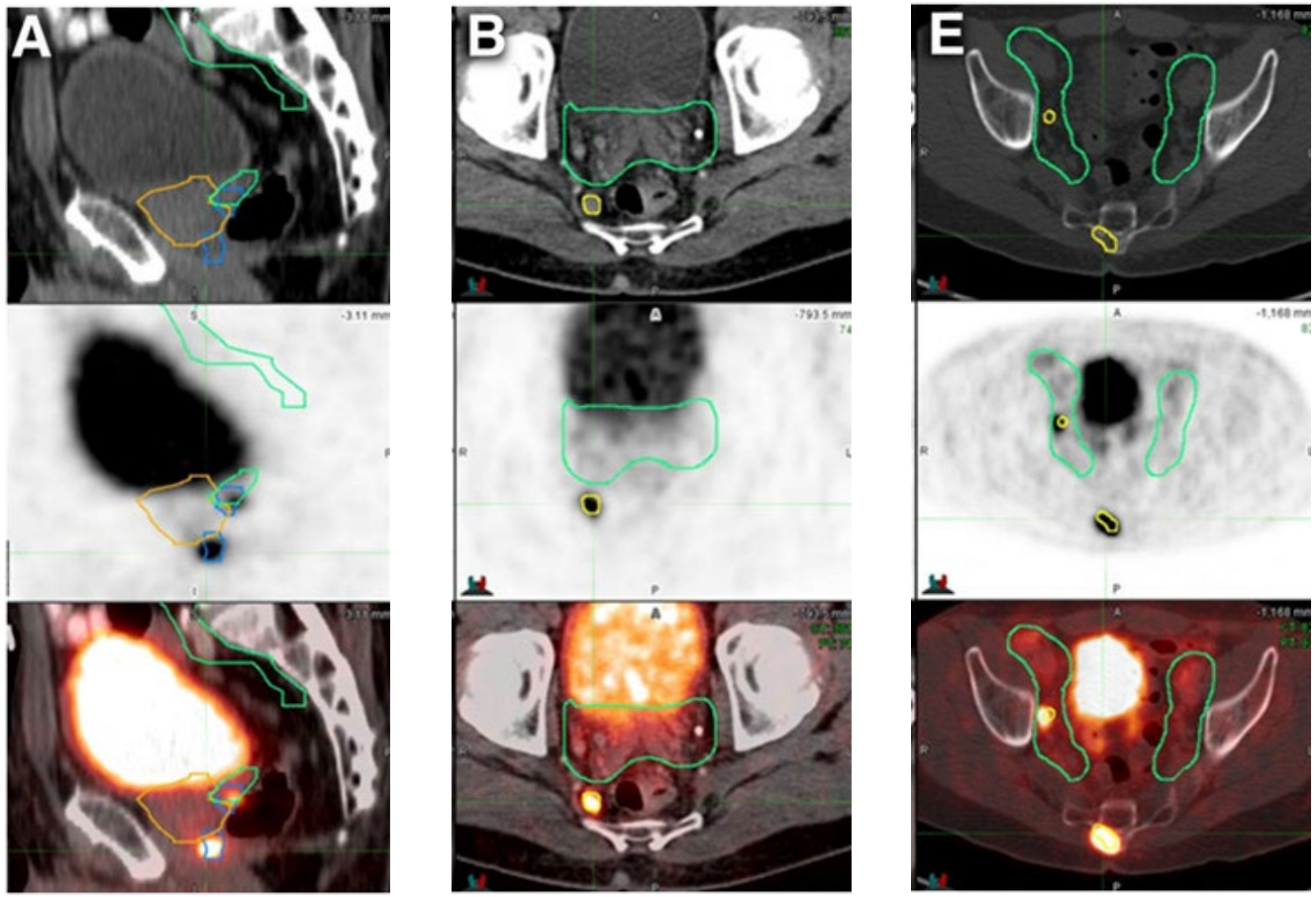

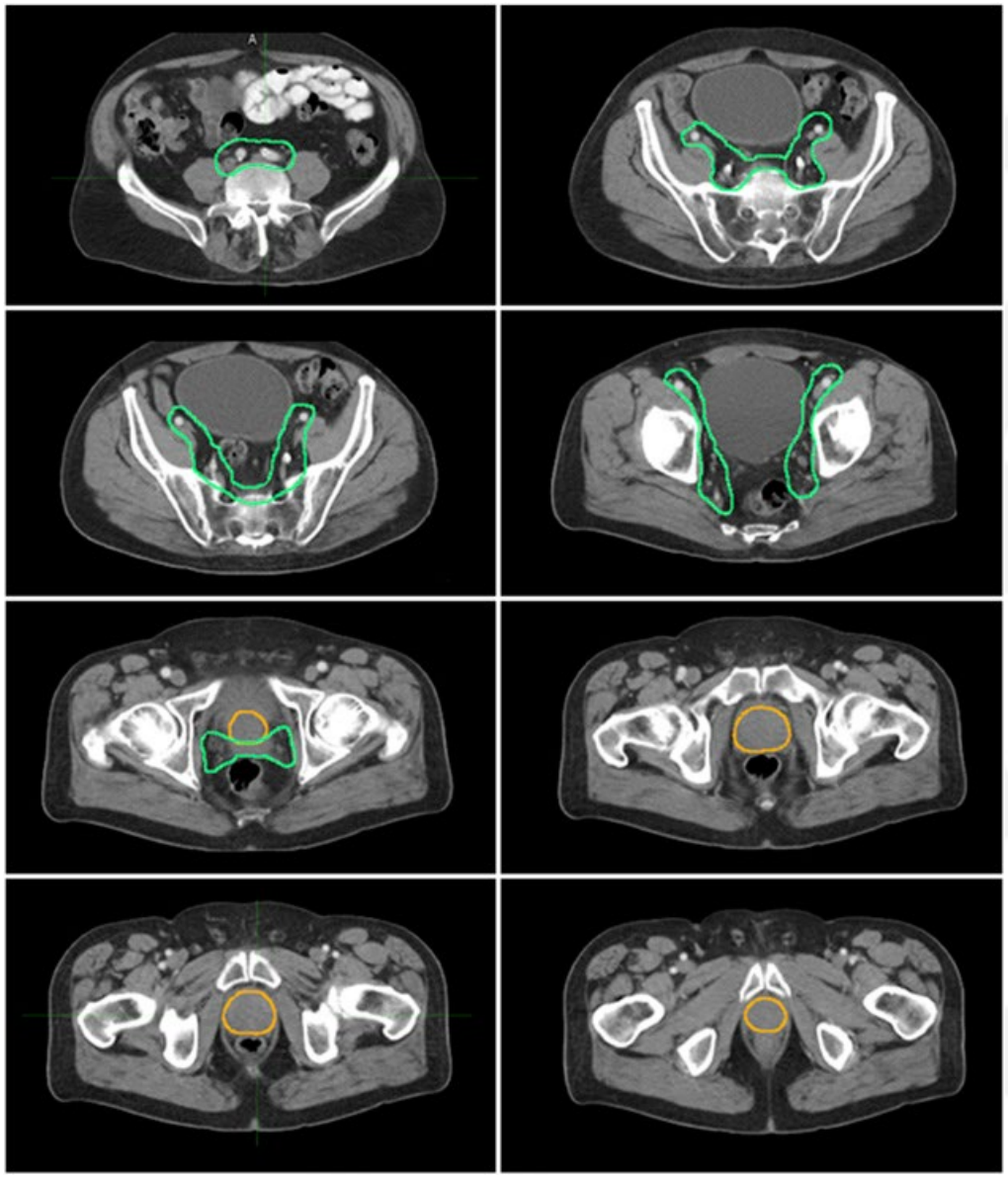

Potential Impact of ^{68}Ga-PSMA-11 PET/CT on the Planning of Definitive Radiation Therapy for Prostate Cancer

Jeremie Calais, Amar U. Kishan, Minsong Cao, Wolfgang P. Fendler, Matthias Eiber, Ken Herrmann, Francesco Ceci, Robert E. Reiter, Matthew B. Rettig, John V. Hegde, Narek Shaverdian, Chris R. King, Michael L. Steinberg, Johannes Czernin and Nicholas G. Nickols

J Nucl Med. 2018;59:1714-1721.
Published online: April 13, 2018.
Doi: 10.2967/jnumed.118.209387

Agenda

- Estadiamento local (T)
- Estadiamento regional (N)
- Estadiamento sistêmico (M)
- Planejamento terapêutico
  - Cirurgia
  - Radioterapia
- Impacto clínico
- Perspectivas

Impacto clínico

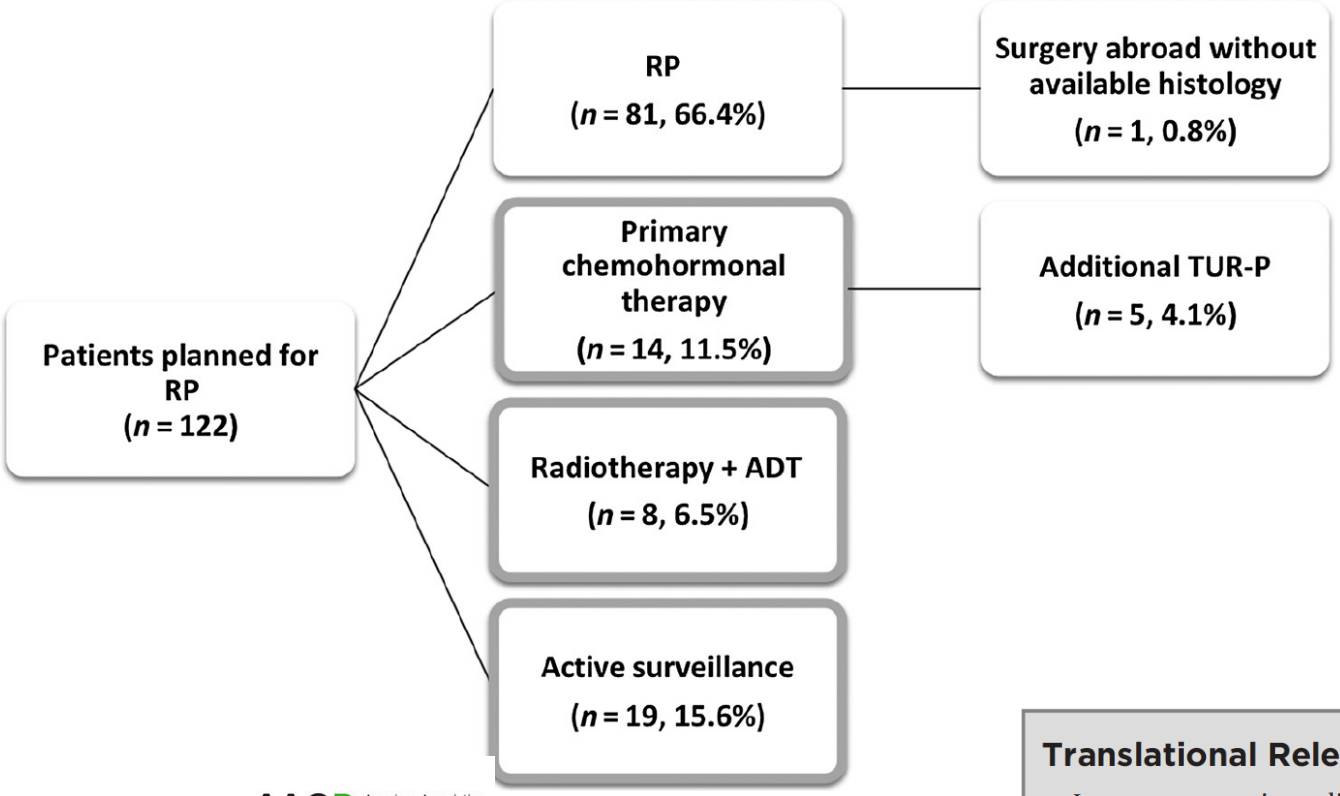

AACR American Association for Cancer Research

Clinical Cancer Research

PSMA Ligand PET/MRI for Primary Prostate Cancer: Staging Performance and Clinical Impact

Bernhard Grubmüller, Pascal Baltzer, Sabrina Hartenbach, et al.

Clin Cancer Res Published OnlineFirst August 23, 2018.

Translational Relevance

In a prospective diagnostic study of 122 patients, [^{68}Ga]Ga-PSMA-11 (PSMA)-PET/MRI demonstrated high staging performance. The treatment was changed accordingly in almost a third of the patients. Whole-body staging with PSMA-PET/MRI can noninvasively provide important information for therapeutic strategies and enables a more personalized concept.

Agenda

- Estadiamento local (T)
- Estadiamento regional (N)
- Estadiamento sistêmico (M)
- Planejamento terapêutico
  - Cirurgia
  - Radioterapia
- Impacto clínico
- Perspectivas

Detecção

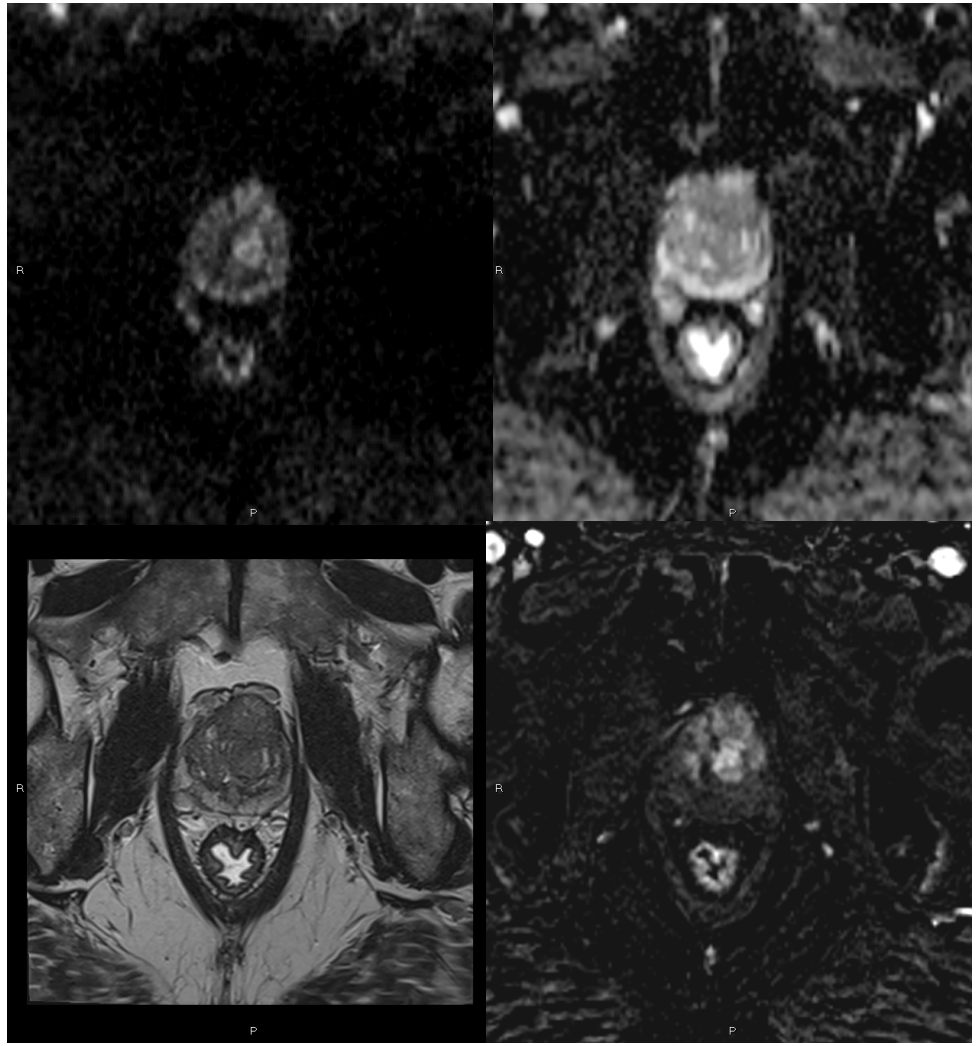

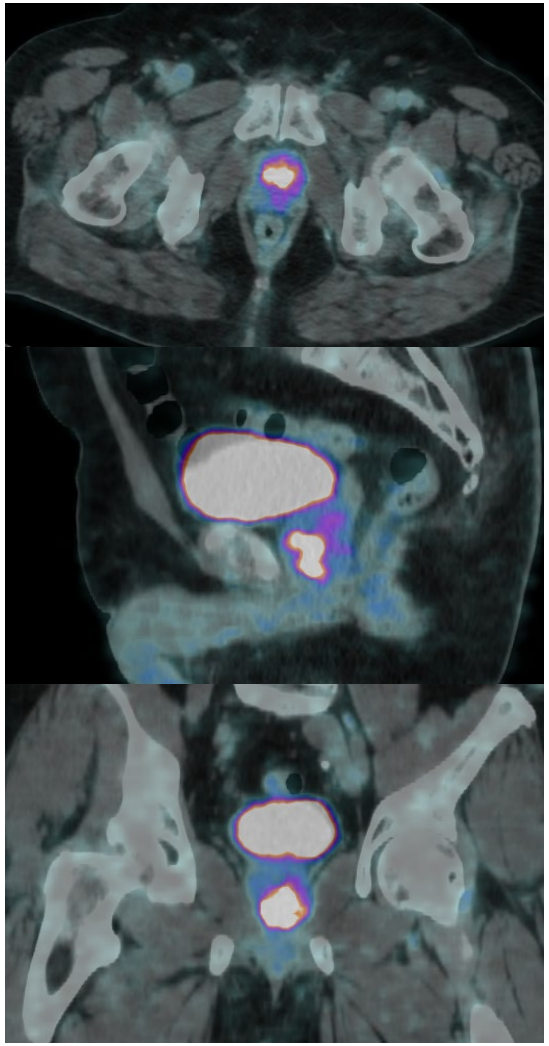

69 anos, investigação de PSA = 25 ng/ml → Gleason 7b

Detecção

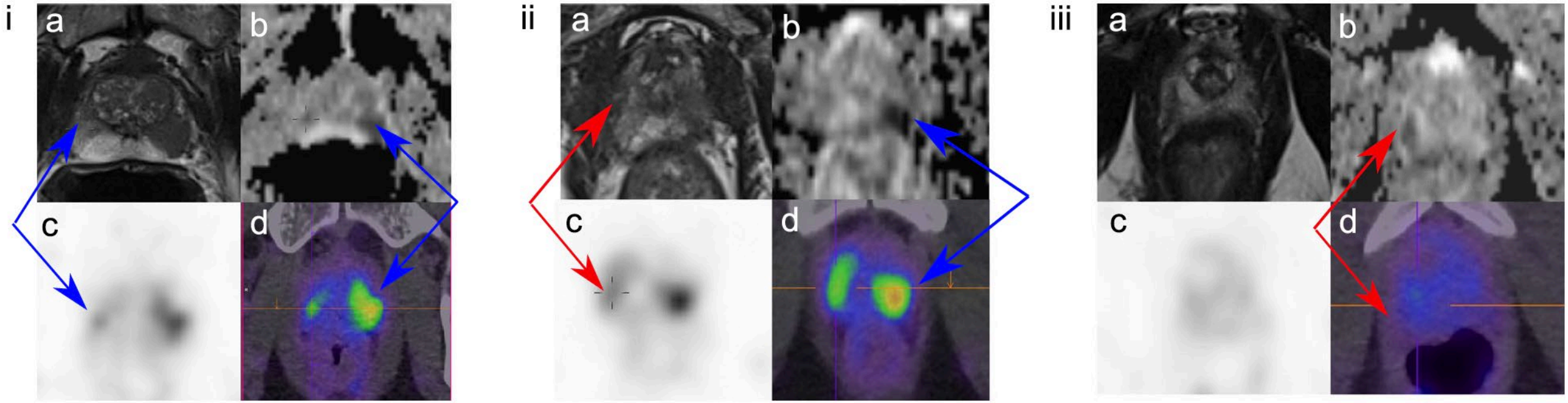

European Journal of Nuclear Medicine and Molecular Imaging
https://doi.org/10.1007/s00259-018-4160-7

ORIGINAL ARTICLE

CrossMark

Improved specificity with ^{68}Ga PSMA PET/CT to detect clinically significant lesions "invisible" on multiparametric MRI of the prostate: a single institution comparative analysis with radical prostatectomy histology

Peter Donato[1] · Matthew J. Roberts[1,2] · Andrew Morton[2] · Samuel Kyle[2,3] · Geoff Coughlin[1] · Rachel Esler[1] · Nigel Dunglison[1] · Robert A. Gardiner[1,2,4,5] · John Yaxley[1,2]

	mpMRI	PSMA PET/CT
Index Lesion	90%	93%
Bilateral	21%	42%
Multifocal	19%	34%

Guiar biópsia

1) ^{68}Ga-PSMA Staging: Biopsy guidance – ongoing trial

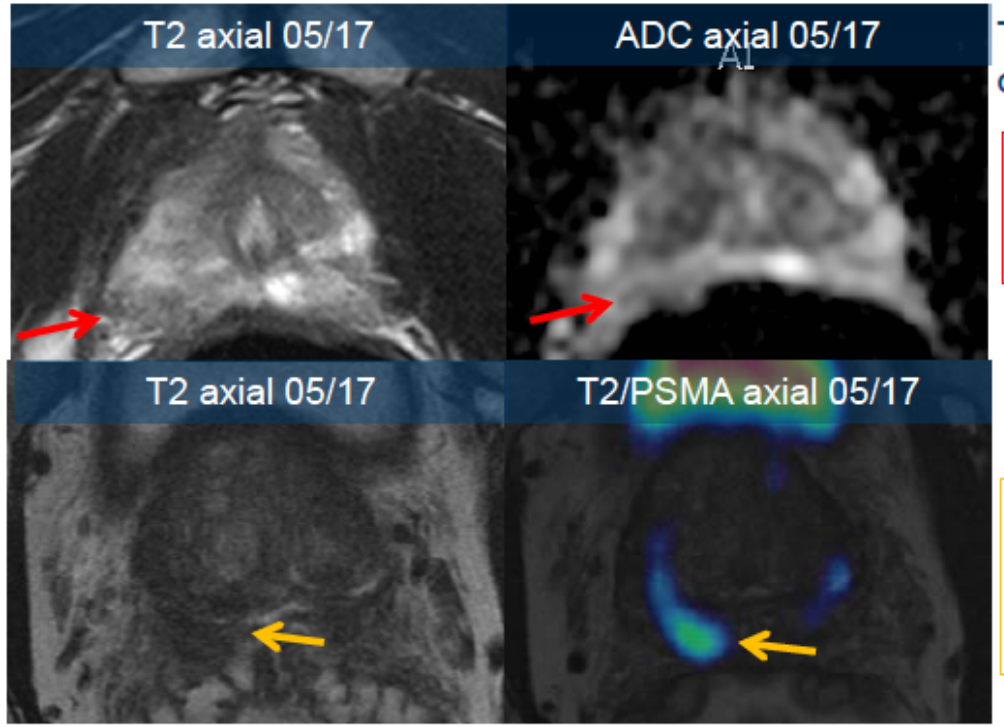

Template biopsy with 37 cores + → 1 core + : 1.6 mm, GS 3+4

3 biopsy cores midglandular right peripheral lateral → 3 cores - : negative

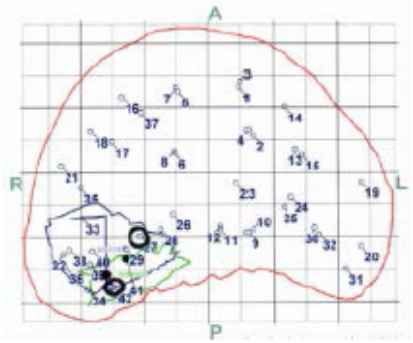

3 biopsy cores at the base right peripheral paramedial → 3 cores +: positive (max 7.5 mm, GS 3+4)

UniversitätsSpital Zürich

PSMA-PET/MR might be superior to mpMRI for targeted biopsy with a higher detection rate of the index lesion.

Cortesia da Dra. Irene Burger, USZ

Disponibilidade de radiofármacos

- ^{18}F-PSMA (DCFPyL, PSMA-1007, PSMA-617)
  - Maior meia vida (110min x 67min)
  - Produção: Cíclotron x Gerador
    - Proporciona maior atividade
  - Acurácia semelhante ao ^{68}Ga-PSMA
  - Maior resolução em lesões pequenas

68Ga-PSMA11 18F-DCPyL

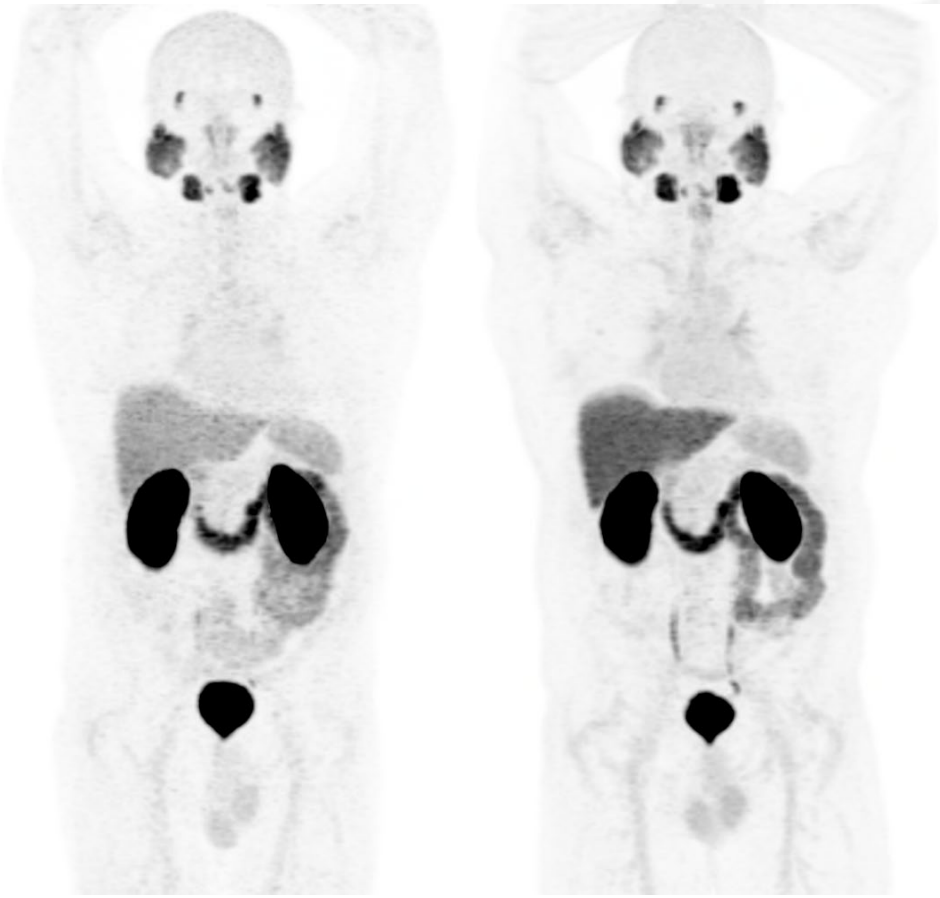

Perspectivas

Primary endpoint

1 Detection of metastatic disease on first-line imaging, being either pelvic nodal (N) or distant metastatic (M) disease

Secondary endpoints

1 Impact of first -line diagnostic imaging on choice of therapy, defined as a decision to alter the original (pre- first-line diagnostic imaging) plan of treatment after considering the result of the first-line diagnostic imaging (impact is categorized as high, medium, low or potential impact ignored)
2 Occurrence of equivocal study results
3 Occurrence of patients who were upstaged by second-line diagnostic imaging, i.e. N0 to N1, M0 or M1, or detection of additional metastases amongst patients with oligometastatic disease
4 Impact of second-line diagnostic imaging on choice of therapy, defined as decision to alter the post first-line diagnostic imaging plan of treatment after considering the result of second-line diagnostic imaging
5 Time to clinical treatment failure defined by biochemical failure, development of metastatic disease or commencement of salvage therapy in patients without distant metastatic disease on PSMA PET/CT
6 Total cost of diagnostic evaluation
7 Total patient radiation exposure (mSv)
8 Reporter agreement in interpretation of on-site readers providing clinical care and those of the central imaging laboratory readers
9 Number of adverse events reported during and post-administration of radiotracer for PSMA PET/CT

BJUI
BJU International

A prospective randomized multicentre study of the impact of gallium-68 prostate-specific membrane antigen (PSMA) PET/CT imaging for staging high-risk prostate cancer prior to curative-intent surgery or radiotherapy (proPSMA study): clinical trial protocol

Michael S. Hofman*†, Declan G. Murphy*†, Scott G. Williams*†, Tatenda Nzenza*†‡, Alan Herschtal§, Richard De Abreu Lourenco¶, Dale L. Bailey**, Ray Budd††, Rodney J. Hicks*†, Roslyn J. Francis‡‡§§ and Nathan Lawrentschuk*†‡

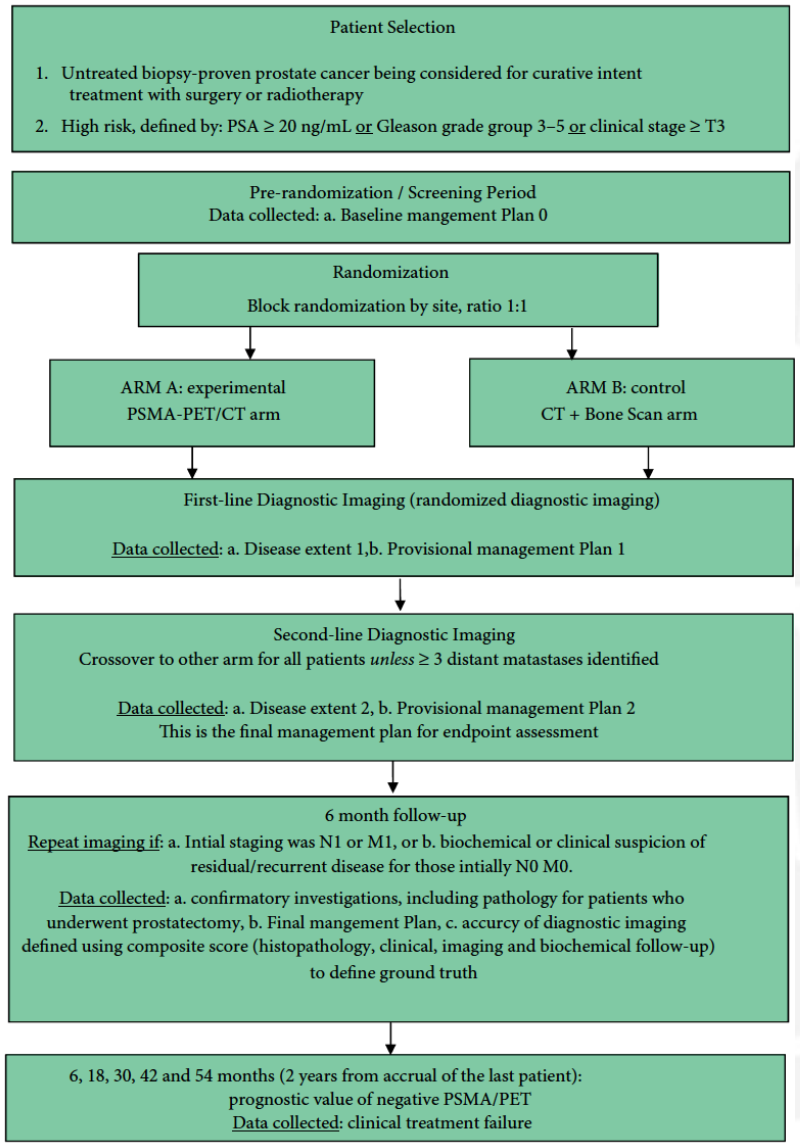

Mensagens finais

- Quando vale a pena pedir PET PSMA pra estadiar CaP?
  - CaP de alto risco
  - Suspeita de tumor de próstata com Bx e/ou RM negativos
- Como o PET PSMA pode influenciar o manejo?
  - Cirurgia → acrescentar LNs em sítios não incluídos no template
  - Radioterapia → alterar o campo da RT
- Quando não vale a pena pedir PET PSMA pra estadiar CaP?
  - CaP de baixo risco
  - CaP de risco intermediário*

Conclusão

- T — TC **RM** PET PSMA
- N — TC RM **PET PSMA**
- M — TC CO RM **PET PSMA**

Obrigado!

marcelo.araujoqueiroz@gmail.com

HOSPITAL SÍRIO-LIBANÊS

MEDICINA USP