



# Clinical Cases Discussion

Thiago Bueno de Oliveira  
Medical Oncology Department  
AC Camargo Cancer Center



**A.C. Camargo**  
Cancer Center

- Speaker: Bayer, Janssen, Astellas, BMS, Merck, MSD, Astra Zeneca, Pfizer
- Sub investigator in sponsored clinical trials: Boehringer Ingelheim, MSD, Janssen, BMS
- Principal investigator in sponsored clinical trials : BMS, Astra Zeneca
- Advisory Board: BMS, Janssen



- MN, 83 years old, Asian, ECOG=1
- Comorbidities: Hypertension, Coronary Arterial Disease (previous revascularization and coronary stents) both controlled and asymptomatic
- 2000: Diagnosis of Prostate Cancer
- cT2aN0M0, Gleason 4+3, Initial PSA=281
- Radiotherapy + 3 years androgen deprivation therapy (goserelin) → nadir PSA=0,6
- Biochemical Recurrence: Intermittent ADT



- 06/2013: Biochemical Progression (PSA=4,13) + bone metastasis  
Bicalutamide + goserelin + zoledronic acid
- 08/2013: Biochemical (PSA=24) and radiological progression (bone)  
Abiraterone + Prednisone
- 02/2014: Biochemical (PSA=43) + Radiological Progression (bone)  
Docetaxel x 5 cycles → Unacceptable Toxicity (PSA=53)



- 09/2014: Biochemical (PSA=91) + Clinical Progression  
Oral Cyclophosphamide + dexamethasone – no response
- 01/2015: Biochemical (PSA=380) + Radiological Progression (bone)  
Cabazitaxel x 10 cycles up to 08/2015 (PSA=77)
- 11/2015: Biochemical (PSA=96) + Clinical Progression  
Enzalutamide with PSA Response (PSA=4,89)

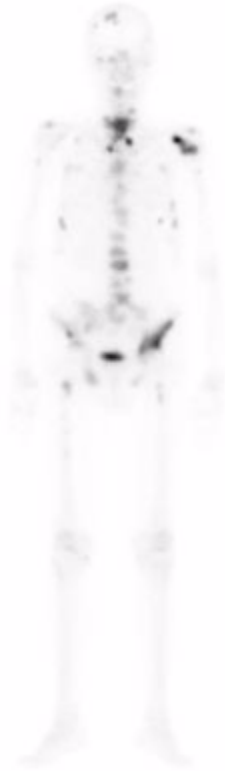

- 01/2017: Biochemical (PSA=22) + Radiological Progression (bone) + Clinical Progression
- Laboratory Results:  
PSA=22 Testosterone<0,03 ALP=247 LDH=386 (ULN 225)  
CEA=2,0  
Hb=13,6 Leucocytes=4450 Platelets=145000  
No renal or hepatic dysfunctions
- Pain medications: Oral Morphine 15 mg / day



# Clinical Case 1 – Bone Scan

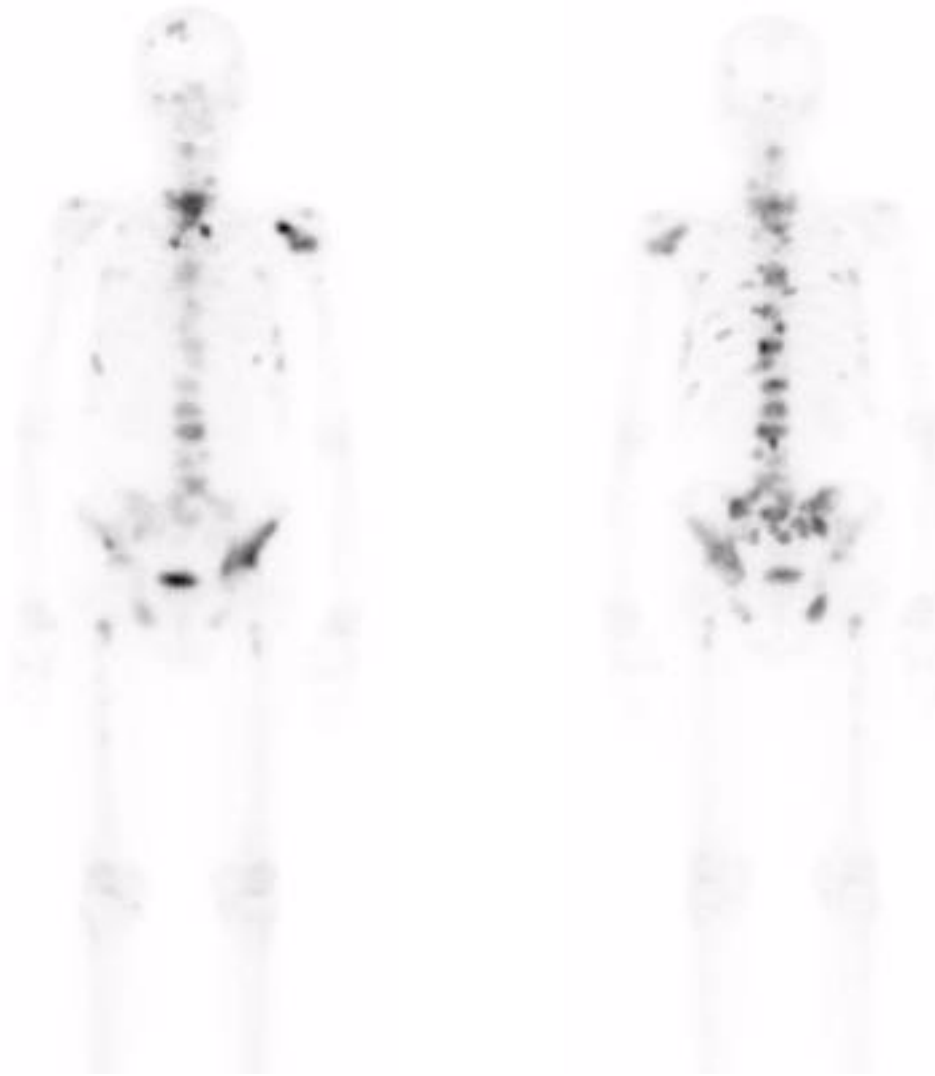
---





# Clinical Case 1 – Bone Scan

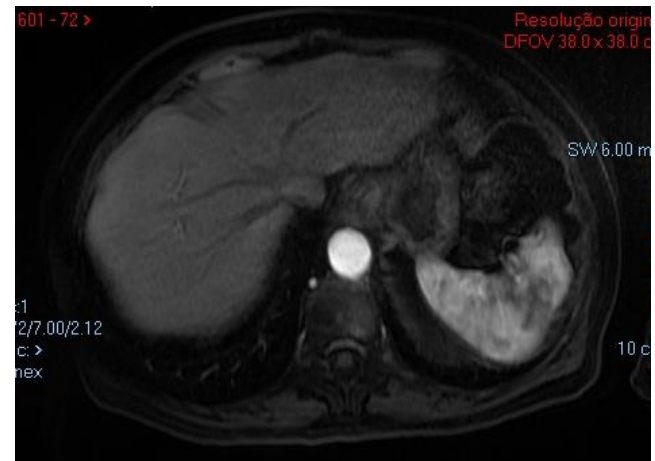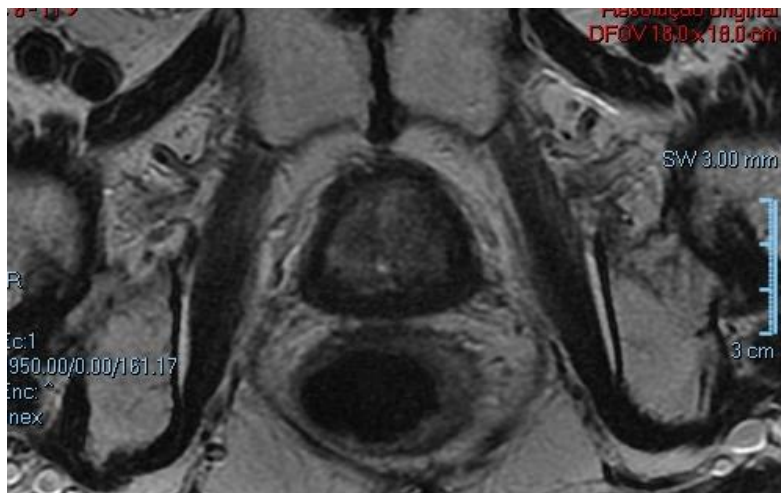
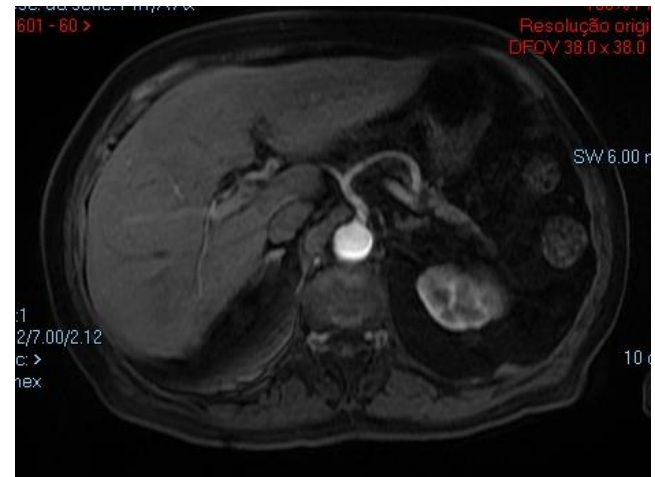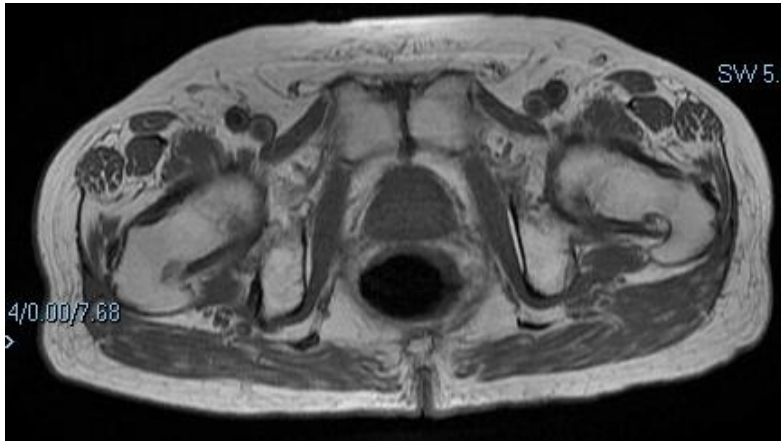---





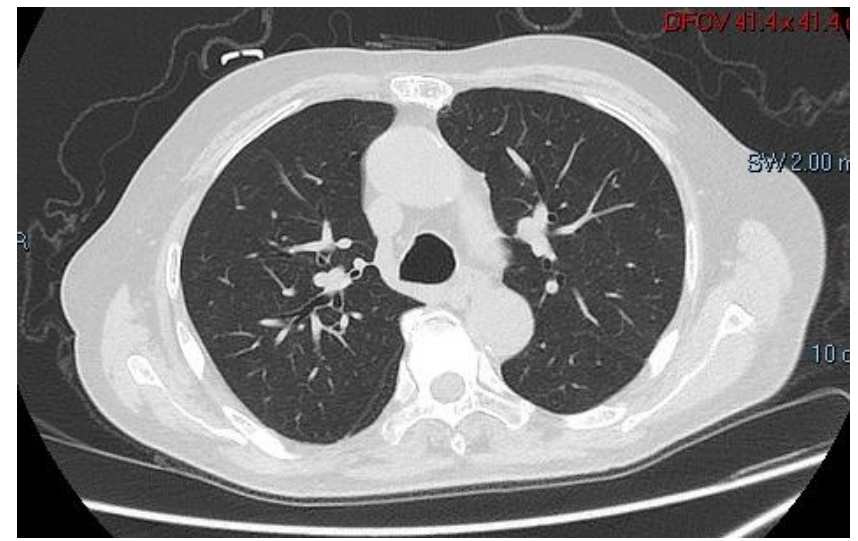
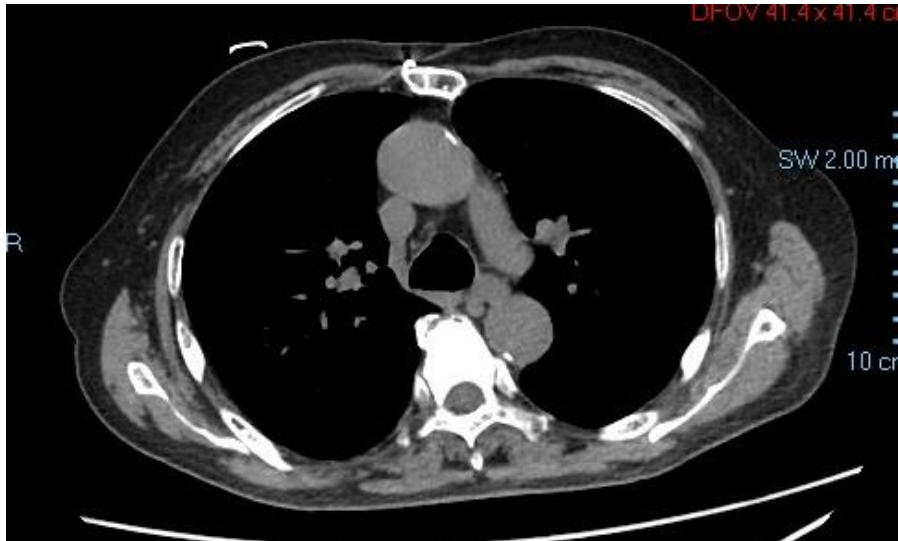

# Clinical Case 1 – MRI A/P





# Clinical Case 1 – Thorax CT



- Symptomatic castration resistant prostate cancer metastatic to the bones, ECOG=1
- Previous treatment: Abiraterone, Docetaxel, oral Cyclophosphamide, Cabazitaxel, Enzalutamide
- No visceral or lymph nodes metastasis
- PSA=22 Testosterone<0,03 ALP=247 LDH=386 CEA=2,0  
Hb=13,6 Leucocytes=4450 Platelets=145000  
No renal or hepatic dysfunctions



- Symptomatic castration resistant prostate cancer metastatic to the bones, ECOG=1
- Previous treatment: Abiraterone, Docetaxel, oral Cyclophosphamide, Cabazitaxel, Enzalutamide
- No visceral or lymph nodes metastasis
- PSA=22 Testosterone<0,03 ALP=247 LDH=386 CEA=2,0  
Hb=13,6 Leucocytes=4450 Platelets=145000  
No renal or hepatic dysfunctions

Treatment??

- Symptomatic castration resistant prostate cancer metastatic to the bones, ECOG=1
- Previous treatment: Abiraterone, Docetaxel, oral Cyclophosphamide, Cabazitaxel, Enzalutamide
- No visceral or lymph nodes metastasis
- PSA=22 Testosterone<0,03 ALP=247 LDH=386 CEA=2,0  
Hb=13,6 Leucocytes=4450 Platelets=145000  
No renal or hepatic dysfunctions

Treatment → Referred to Radium-223 Treatment



- Is it necessary to perform more sensitive imaging evaluation to exclude visceral / lymph node metastasis before the indication of Radium-223?
- For baseline (pre treatment) bone evaluation what is the imaging method of choice?

- Initiated on Radium-223 on February 2017  
PSA=22 / ALP=247 / LDH=386
- 17/02/2017: Cycle 1 Rad-223  
PSA=18 ALP=101 LDH=226 – weaning of opioids
- 07/04/2017: Cycle 2 Rad-223  
PSA=12 ALP=93 LDH=178
- 12/05/2017: Cycle 3 Rad-223  
PSA=29 ALP=79 LDH=165



# Clinical Case 1 - Discussion

---

- How frequent should we perform imaging to exclude visceral / lymph node progression during Radium-223 treatment?
- Is it necessary to re-evaluate bone metastasis with imaging methods during Radium-223 treatment?



- 17/02/2017: Cycle 1 Rad-223  
PSA=18 ALP=101 LDH=226 – weaning of opioids
- 07/04/2017: Cycle 2 Rad-223  
PSA=12 ALP=93 LDH=178
- 12/05/2017: Cycle 3 Rad-223  
PSA=29 ALP=79 LDH=165
- After cycle 3: CT scans of thorax, abdomen and pelvis with no visceral or lymph node progression



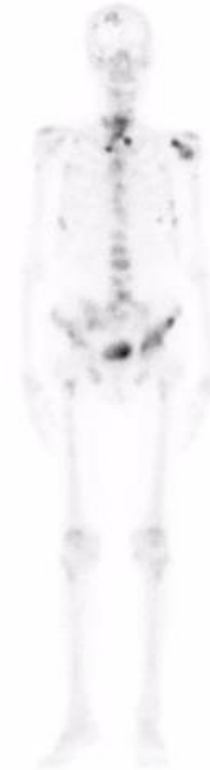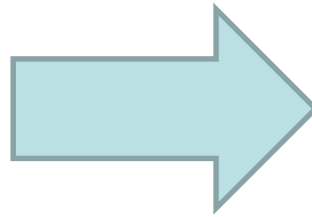
- 16/06/2017: Cycle 4 Rad-223  
PSA=9,1 ALP=68 LDH=120
- 21/07/2017: Cycle 5 Rad-223  
PSA=8,0 ALP=65 LDH=118
- 25/08/2017: Cycle 6 Rad-223  
PSA=9,5 ALP=64 LDH=168
- No hematologic toxicity during the treatment
- Early pain response after cycle 1, with opioids weaning



# Clinical Case – Bone Scan



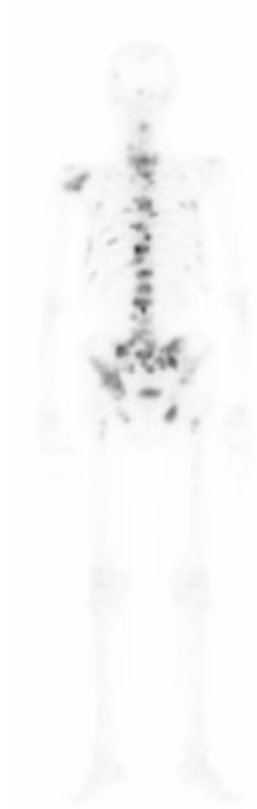**January 2017**



**September 2017**

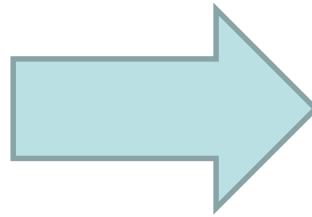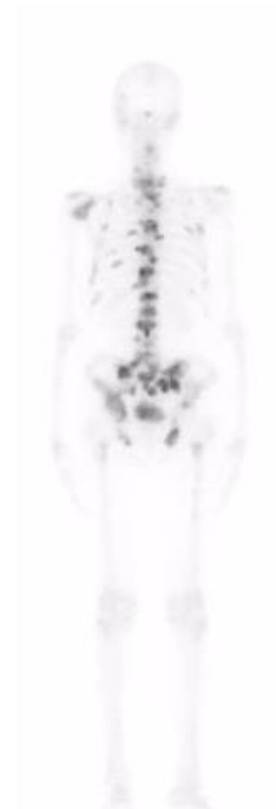


# Clinical Case – Bone Scan



January 2017

---



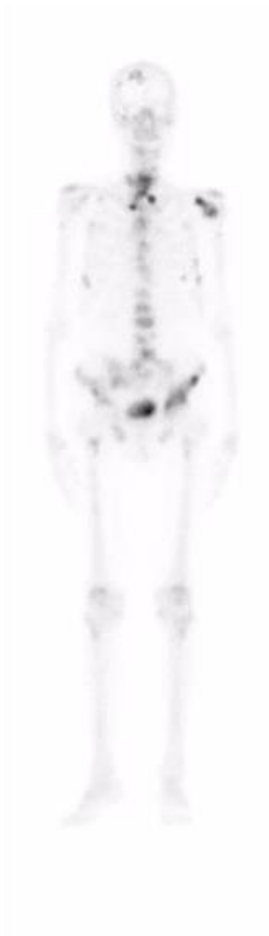September 2017



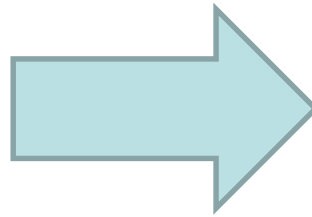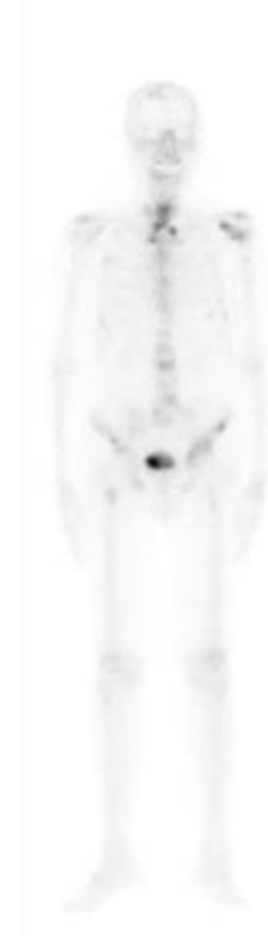
- After 6 cycles of Radium-223 patient stayed on follow up, with no active treatment, with normal life (very good quality of life)
- On January 2018 bone scan with no signs of progression, no visceral disease.
- PSA=9,9 ALP=103 LDH=174
- He is now 84 years old. And counting...



# Clinical Case – Bone Scan



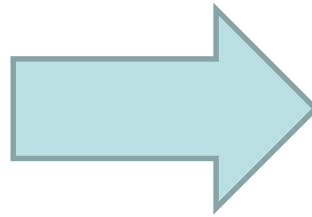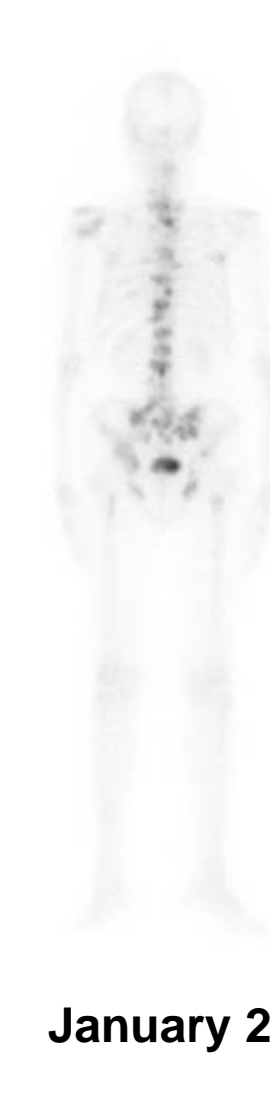
**September 2017**



**January 2018**



# Clinical Case – Bone Scan



- What is the ideal timing for response evaluation after Radium-223?
- Could this patient be re-treated with Radium-223 in the future?



- TK, 86 years old now, asian
- Comorbidities: former-smoker (70 pack-year)
- 2010: Adenocarcinoma of the Prostate, Gleason 8 (4+4) PSA = 50ng/ml  
cT3aN0M0
- 10/2010: Goserelin
- 01/2011 to 02/2011: Radiotherapy
- 07/2011: Nadir PSA = 0,043
- Continued on ADT – planning of 2 to 3 years

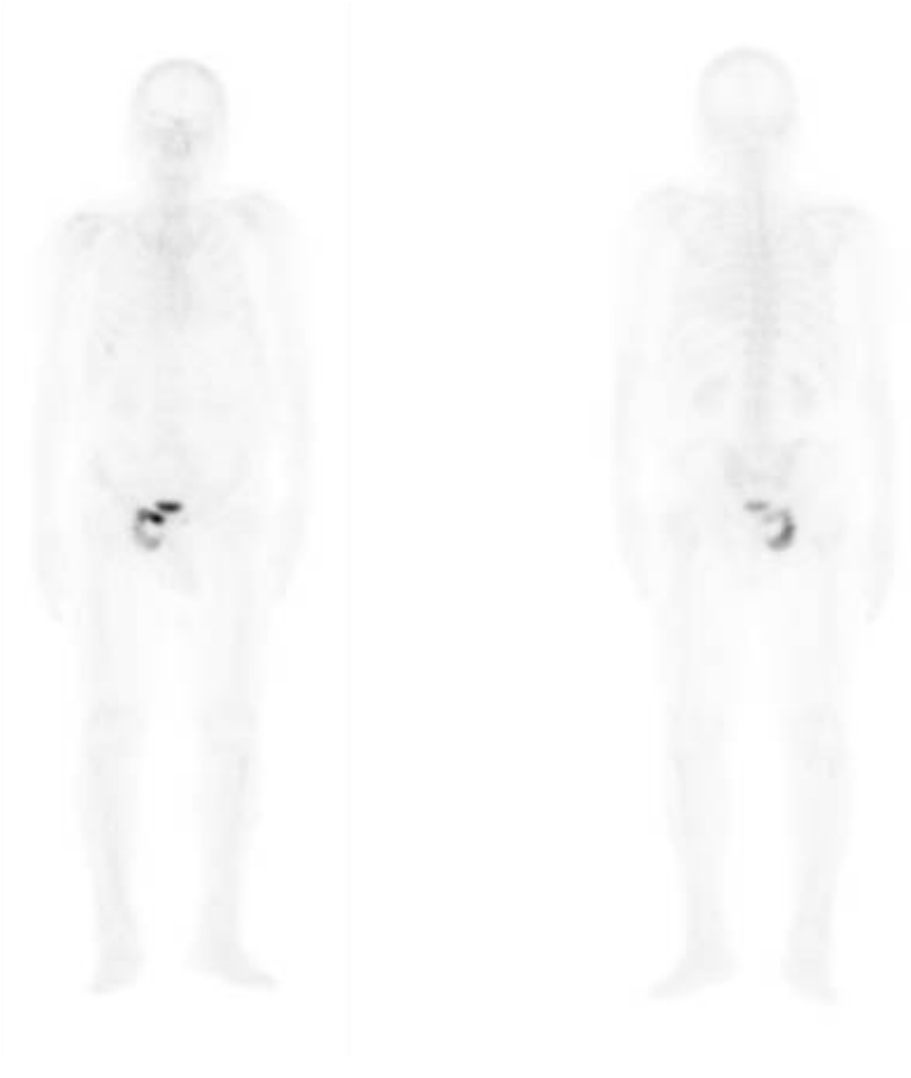

- 05/2012: Biochemical recurrence PSA = 3,8ng/ml Test = 27  
No evidence of metastasis – M0  
Association of bicalutamide to goserelin
- 08/2012: PSA = 0,85ng/ml
- 02/2013: PSA=4,9 – Still M0 – Asymptomatic  
Interrupted Bicalutamide – Keep on ADT
- 07/2014: PSA=19,0 + Radiological progression to the bones

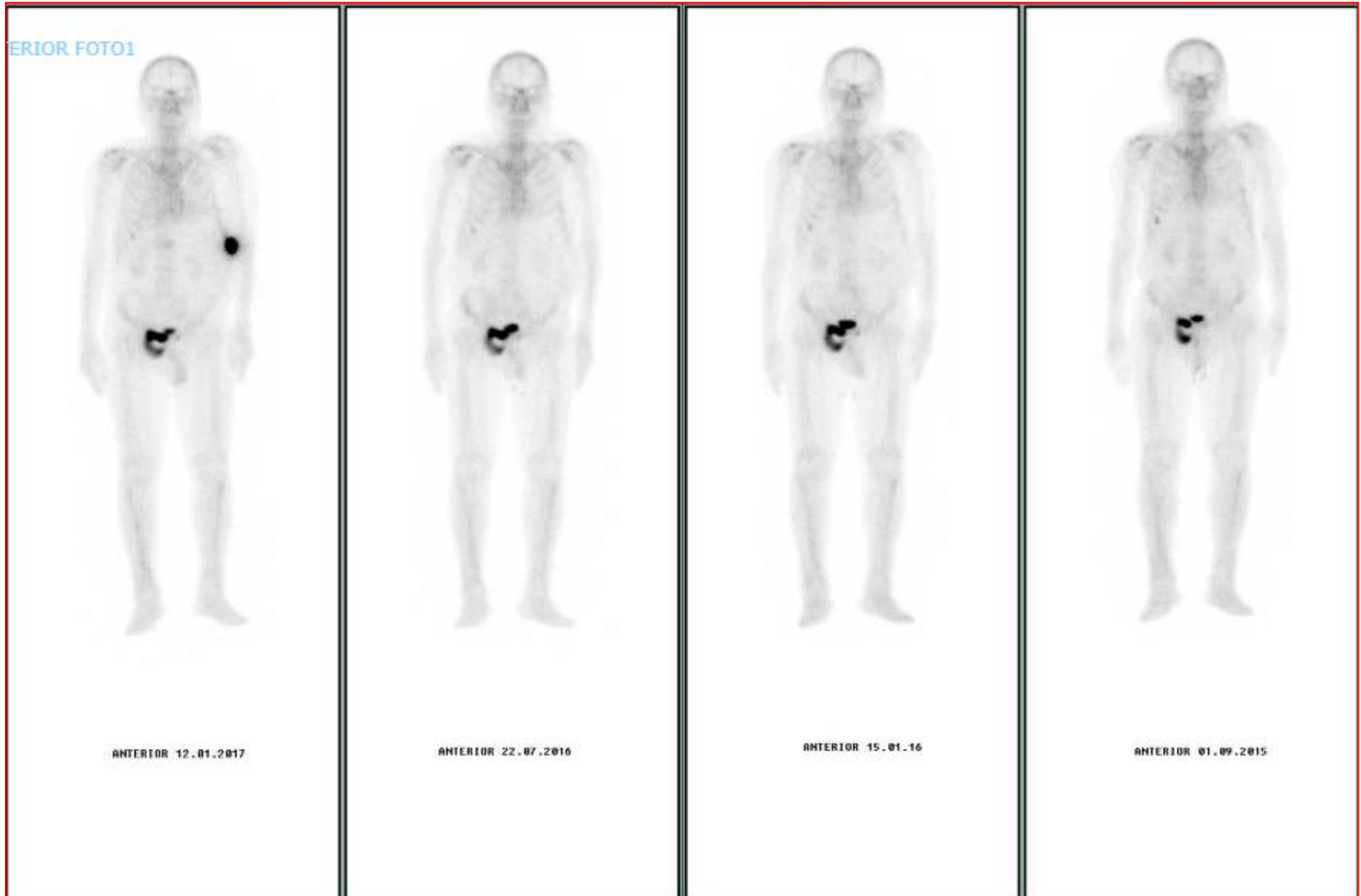- 07/2014: PSA=19,0 + Radiological progression to the bones
- Started on Abiraterone + prednisone + zoledronic acid
- 10/2014: PSA=0,40
- 05/2015: PSA=4,9 – No radiological or clinical progression
- 09/2015: PSA=27 – No radiological or clinical progression
- 03/2016: PSA=66 – Radiological progression on the bones
- Asymptomatic

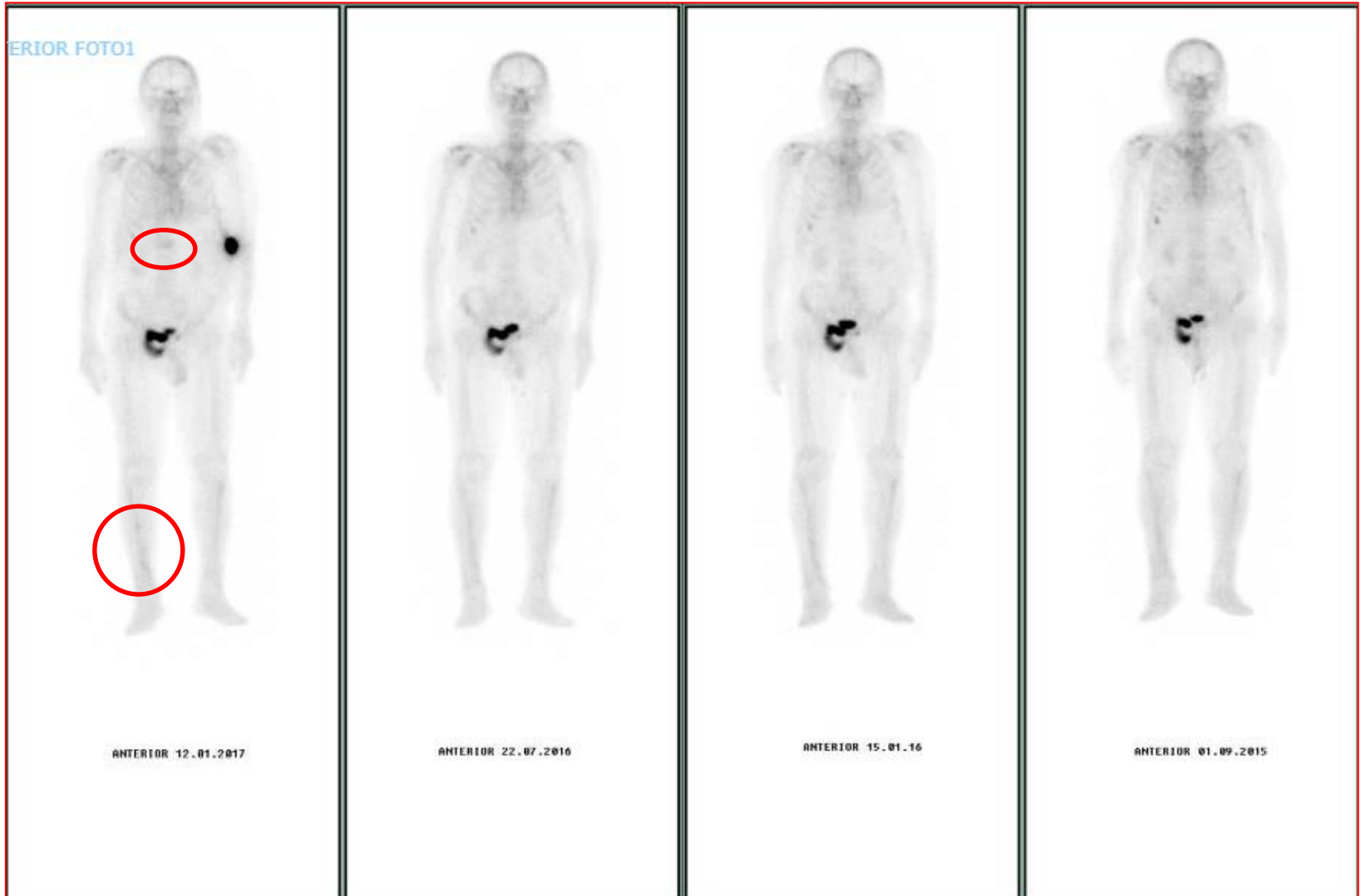

# Bone Scan – 03/2016



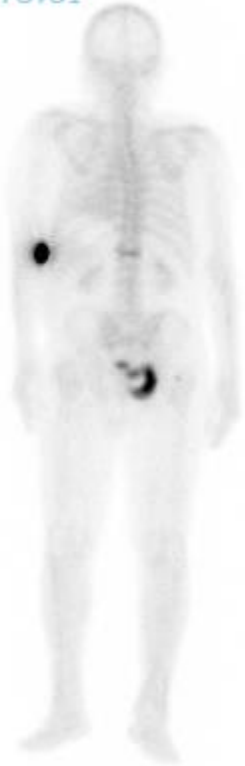- 03/2016: PSA=66 – Radiological progression on the bones
- Asymptomatic
- Didn't want IV chemo – wanted to fish...
- Started on oral cyclophosphamide
  
- 05/2016: PSA=24
  
- 10/2016: PSA=38
  
- 01/2017: PSA=50 – Radiological progression on the bones
- Asymptomatic



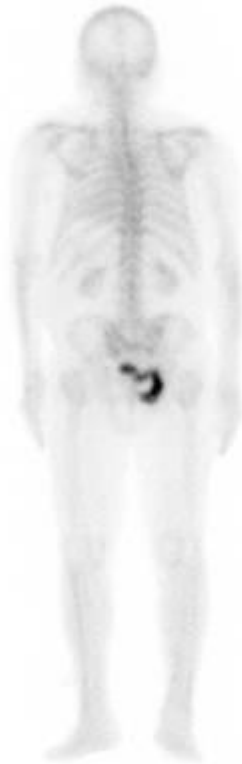



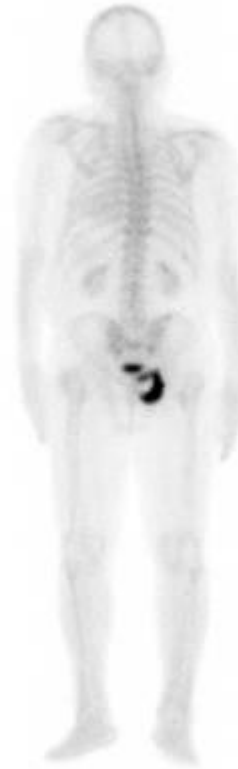TERIOR FOTO1



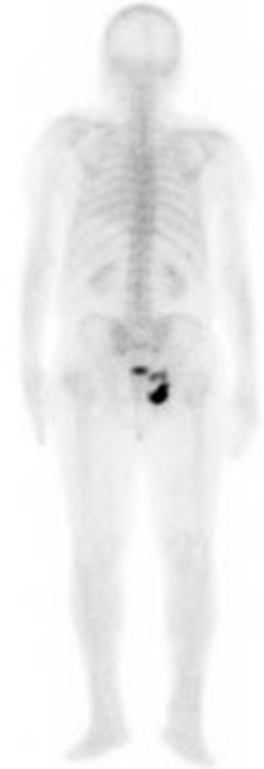POSTERIOR 12.01.2017



POSTERIOR 22.07.2016



POSTERIOR 15.01.2016

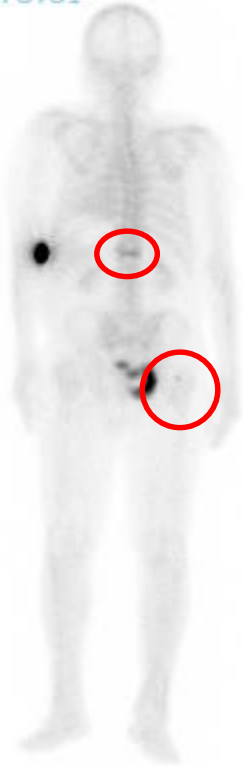

POSTERIOR 01.09.2015





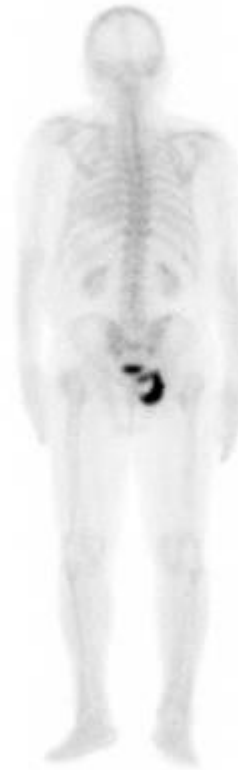TERIOR FOTO1



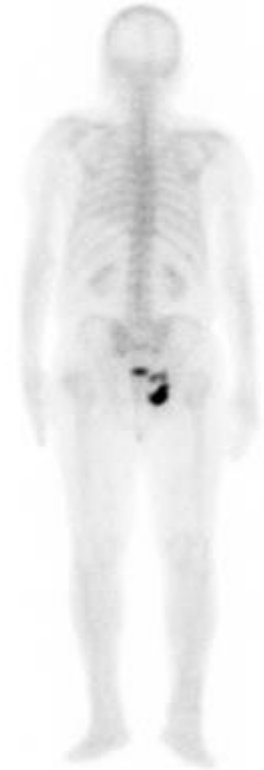POSTERIOR 12.01.2017



POSTERIOR 22.07.2016



POSTERIOR 15.01.2016



POSTERIOR 01.09.2015



# Clinical Case 2 - Discussion

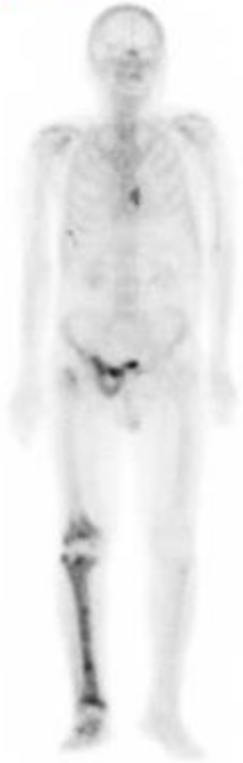---

- Would you start Radium-223 in this asymptomatic patient at this time point?
- Do you feel comfortable to extrapolate the results of ALSYMPCA to asymptomatic patients?

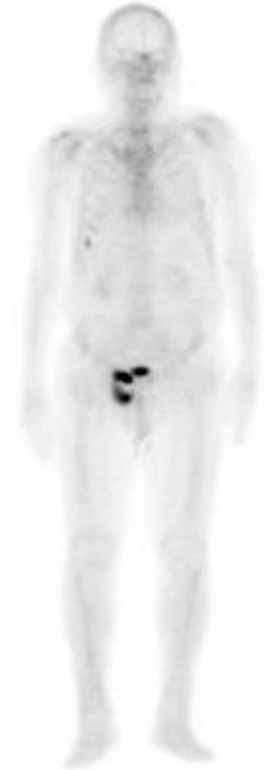
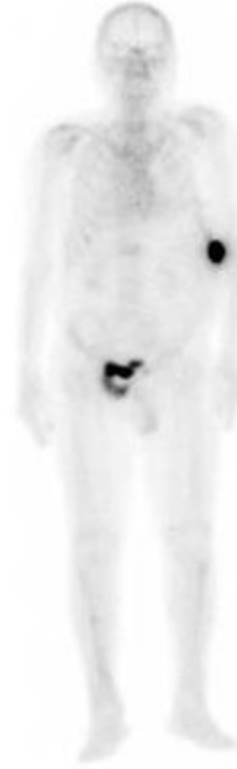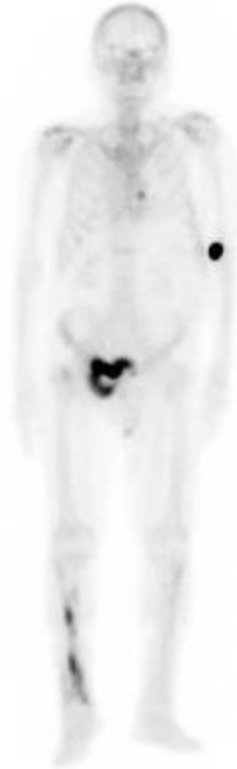- 01/2017: PSA=50 – Radiological progression on the bones, asymptomatic
- 02/2017: Enzalutamide
- 05/2017: PSA=124 + Radiological progression to the bones
- Clinical progression: pain in the right hip and right leg (tibia)
- Couldn't fish anymore
- No visceral or lymph node metastasis
- No evident lesion on the prostate



RIOR FOTO2

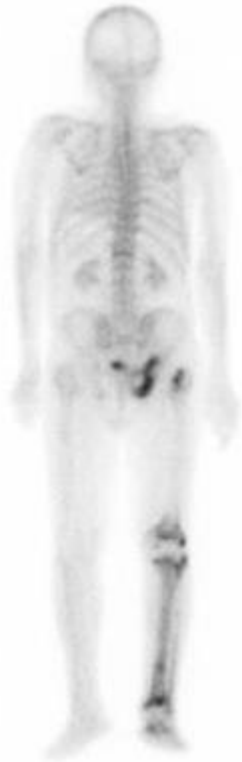

05/2017

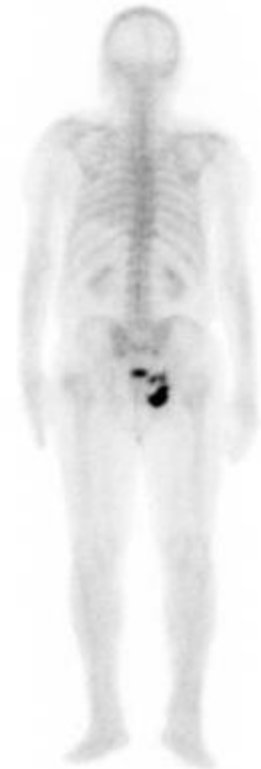
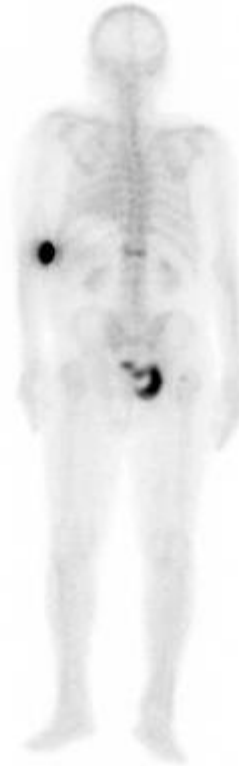
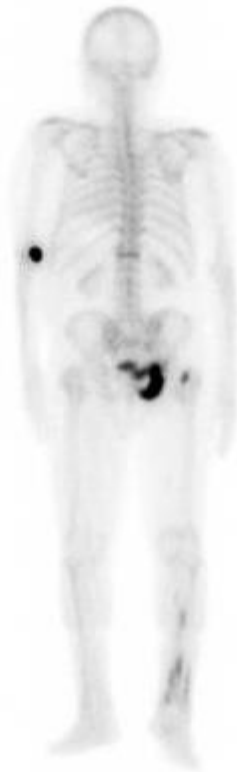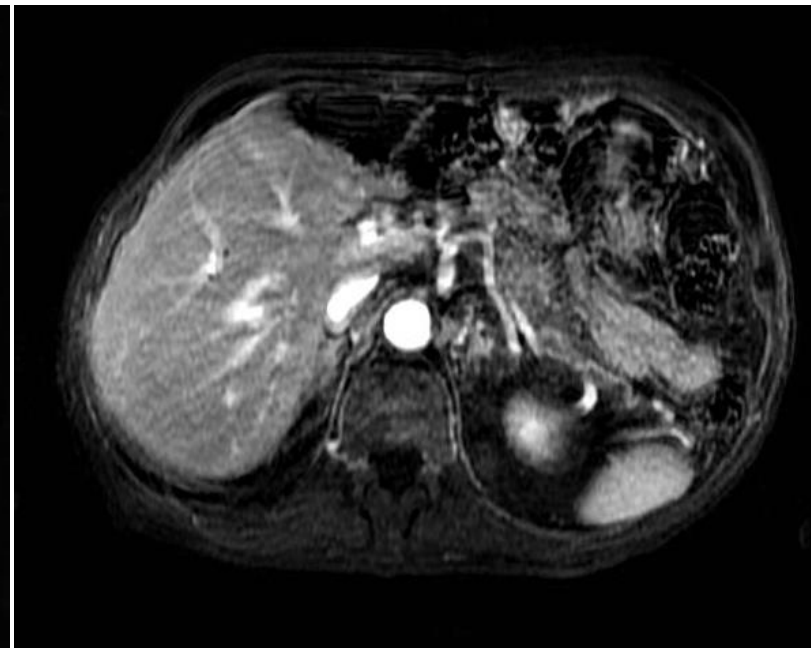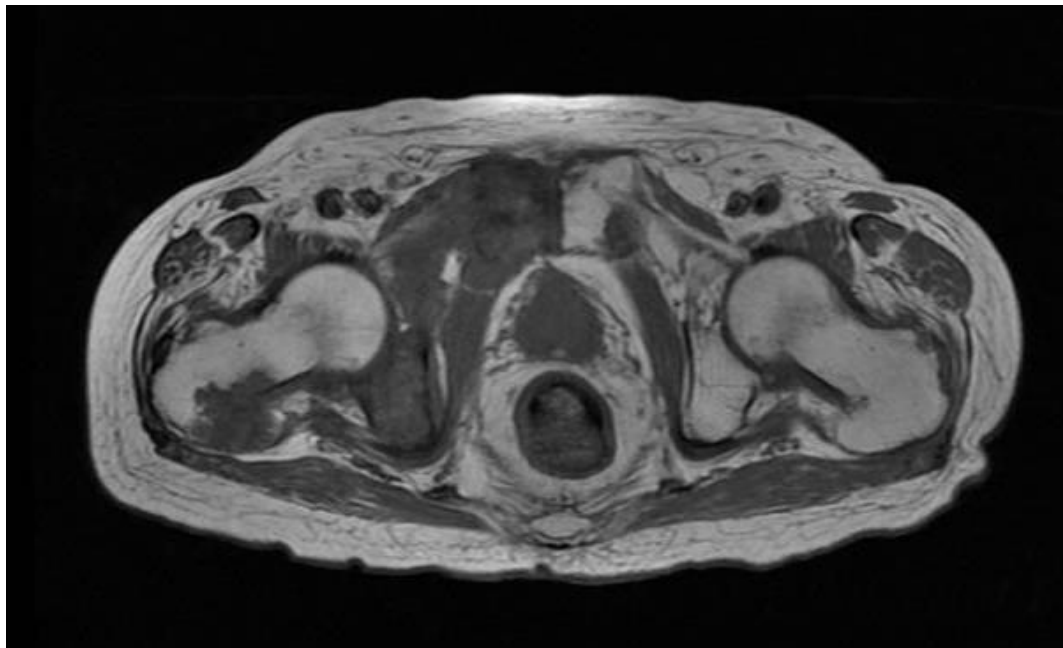


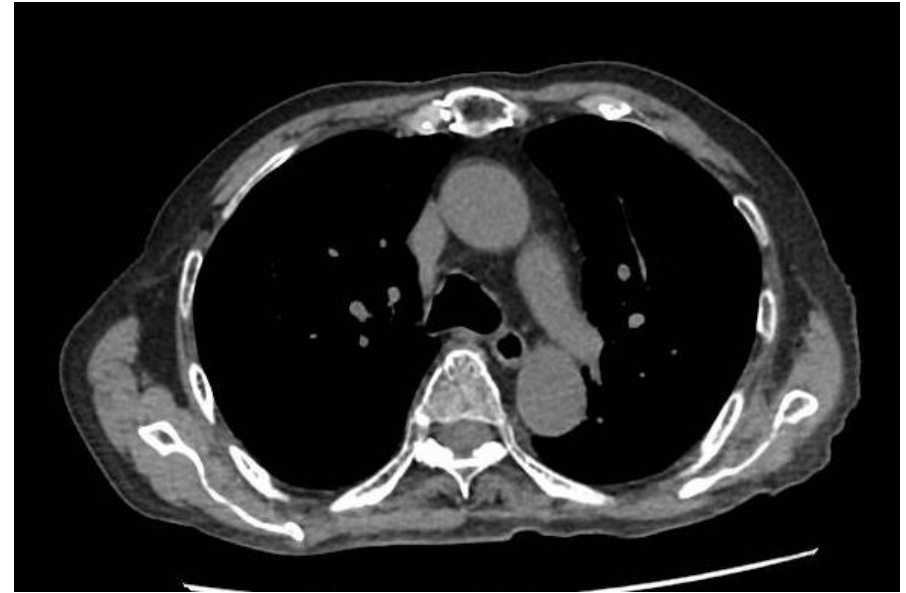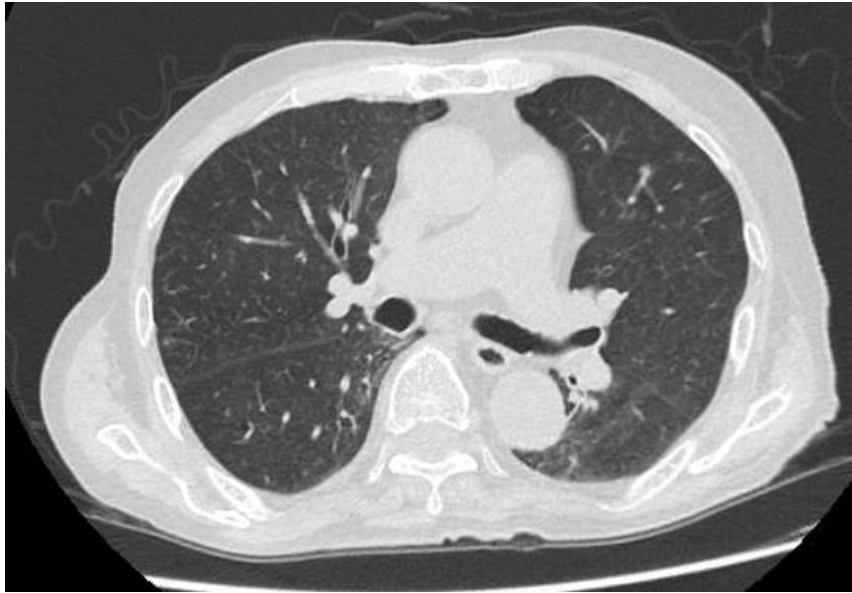ERIOR FOTO2



05/2017









- 05/2017: PSA=124 + Radiological progression to the bones
- Clinical progression: pain in the right hip and right leg
- Morphine 30 mg/day
- No local disease, no lymph node or visceral metastasis
  
- Treatment ?





- 05/2017: PSA=124 + Radiological progression to the bones
- Clinical progression: pain in the right hip and right leg
- Morphine 30 mg/day
- No local disease, no lymph node or visceral metastasis
  
- Treatment → Referred to Radium-223
  
- Referred to radiation-oncology – discuss indication of radiotherapy in the symptomatic lesions (right tibia and right hip)



- 05/2017: PSA=124 ALP=152 LDH=348 (ULN 480)
- 06/2017: Cycle 1 Radium-223
- 07/2017: Cycle 2 Radium-223
- 08/2017: -> After 2 cycles of Radium-223  
PSA=164 ALP=133 LDH=319
- Pain response after 2 cycles – weaning of opioids
- Radiation oncology evaluation: contra indicated due to early pain response to Radium-223



- 08/2017: Cycle 3 Radium-223  
PSA=179 ALP=135 LDH=315
- 09/2017: Cycle 4 Radium-223  
PSA=246 ALP= 126 LDH=330  
Maintaining clinical benefit – no pain at all



- 08/2017: Cycle 3 Radium-223  
PSA=179 ALP=135 LDH=315
- 09/2017: Cycle 4 Radium-223  
PSA=246 ALP= 126 LDH=330  
Maintaining clinical benefit – no pain at all
- 10/2017: Cycle 5 Radium-223  
PSA=231 ALP=146 LDH=287
- 11/2017: Cycle 6 Radium-223  
PSA=205 ALP=158 LDH=280

- GI diarrhea, no hematologic toxicity, no other toxicities
- 01/2018:
- PSA=120 ALP=127 LDH=280
- No active treatment
- No pain
- Good quality of life
- Fishing again
- Waiting for response evaluation imaging



Obrigado pela atenção

[thiago.oncologia@gmail.com](mailto:thiago.oncologia@gmail.com)



# BACKUP CASE

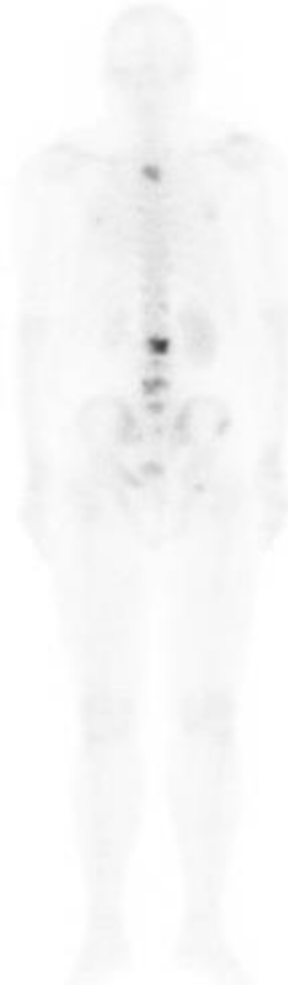
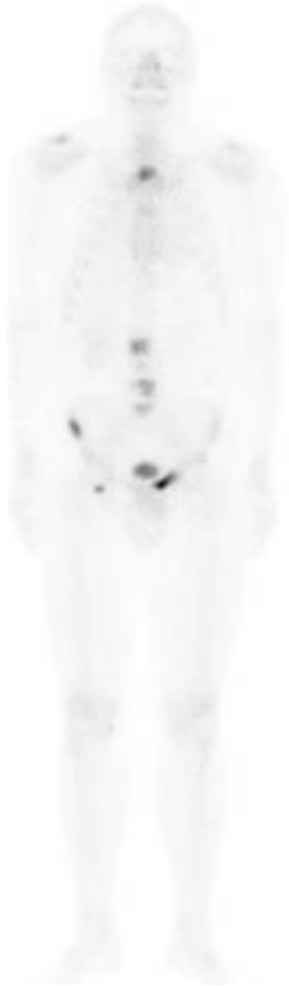
- LS, 56 years-old, Engineer
- No comorbidities
  
- January 2015: back pain
  
- August 2015:
  - MRI and bone scan with multiple bone lesions
  - Biopsy of the prostate: Adenocarcinoma gleason 4+4
  - PSA=1504
  - No lymph node or visceral metastasis
  
- Adenocarcinoma of the prostate cT2aN0M1
- High volume disease



# Clinical Case 3 – Bone Scan

---



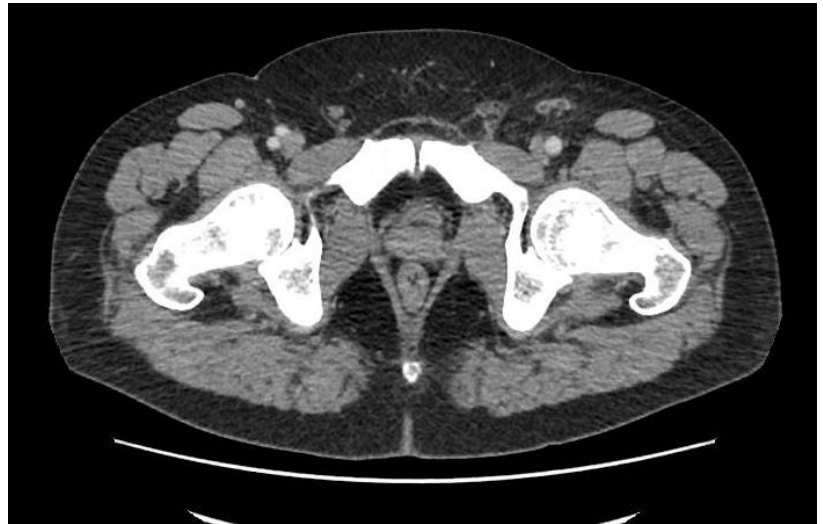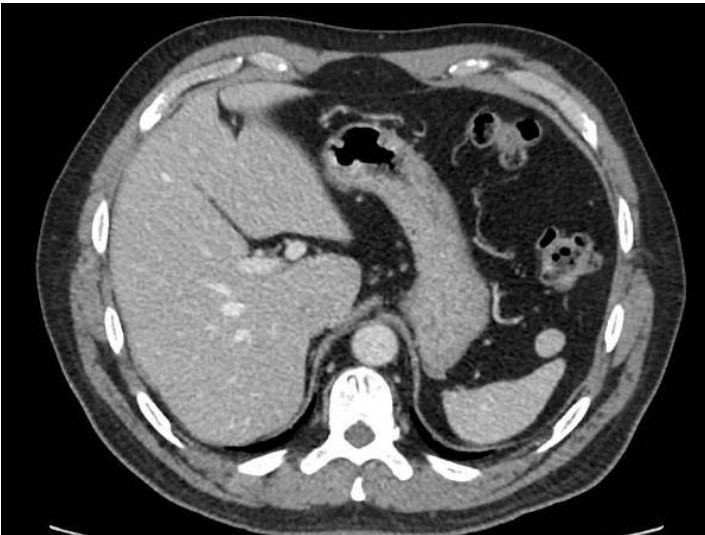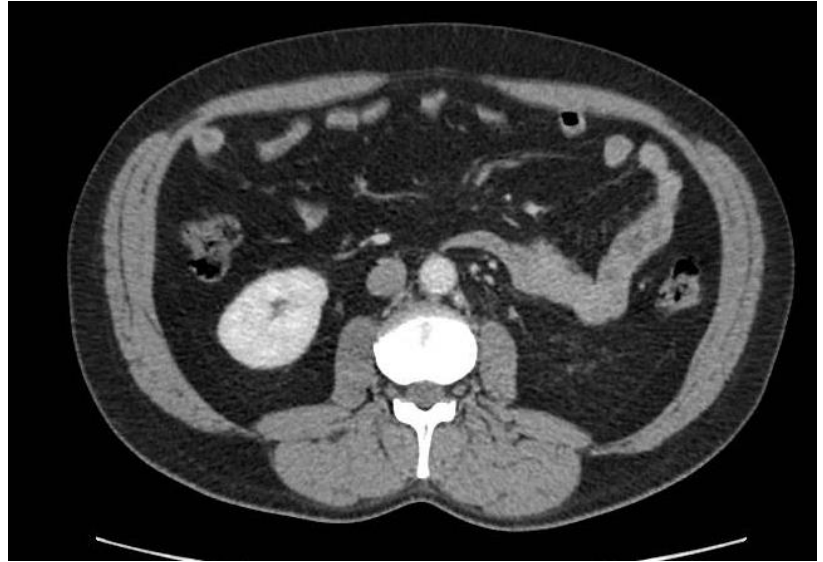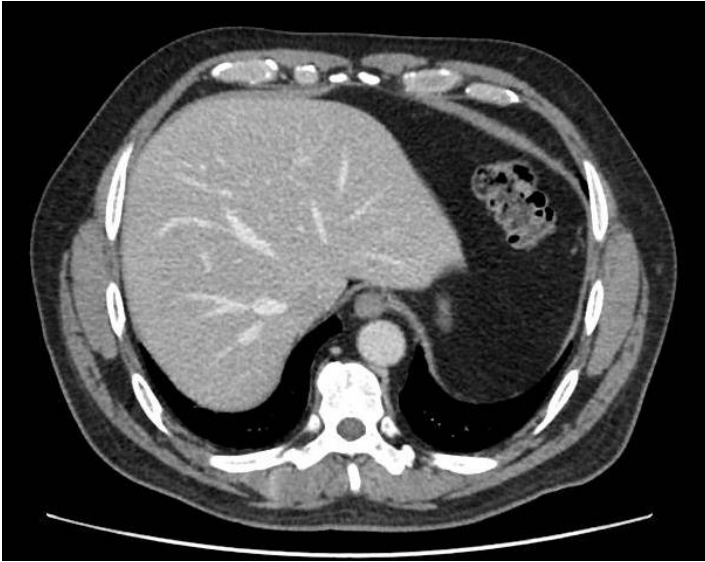
- Adenocarcinoma of the prostate gleason 8, cT2aN0M1
- High volume disease
- September 2015: Goserelin
- Docetaxel x 6 cycles from september/2015 to january/2016
- April/2016 → PSA=20,0 – no back pain anymore
- February/2017 → Nadir PSA=5,0



- 02/2017: PSA=5,0
- 06/2017: PSA=6,6 – No clinical or radiological progression
- 09/2017: PSA=8,5 – No clinical or radiological progression
- 01/2018: PSA=9,9
- Back pain requiring codein 3 times a week



# Clinical Case 3 – CT Scans





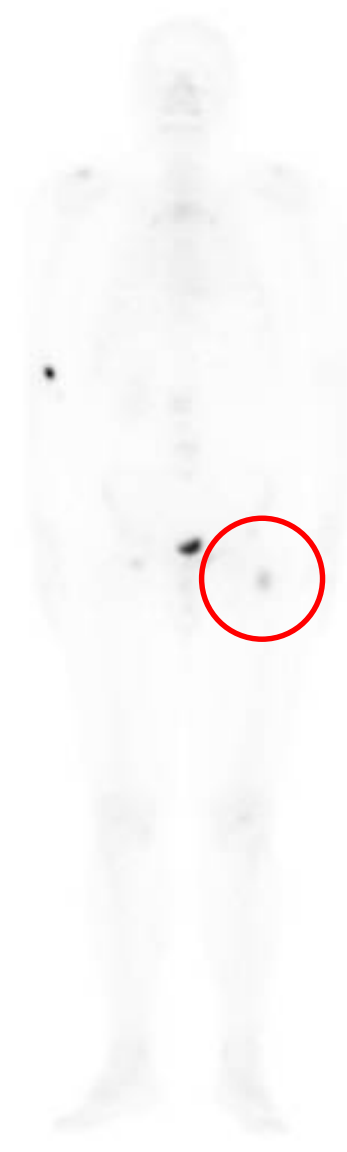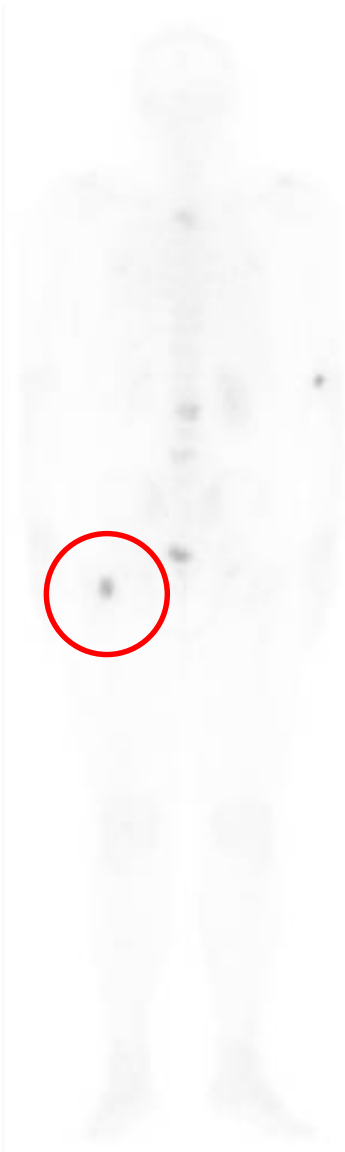# Clinical Case 3 – Bone Scan

---





# Clinical Case 3 – Bone Scan





- Castration resistant prostate cancer with bone metastasis post  
Charted
- 01/2018: PSA=9,9 ALP=62 LDH=271 (ULN 350)
- Back pain requiring codein 3 times a week
- Imaging with no visceral or lymph node metastasis, no evident  
lesion on the propstate, 1 new lesion (proximal femur) on bone scan
- Treatment?





- Castration resistant prostate cancer with bone metastasis post  
Charted
- 01/2018: PSA=9,9 ALP=62 LDH=271 (ULN 350)
- Back pain requiring codein 3 times a week
- Imaging with no visceral or lymph node metastasis, no evident  
lesion on the propstate, 1 new lesion (proximal femur) on bone scan
- Treatment → Referred to Radium 223 treatment

- What is the optimal timing of Radium-223 treatment?
- Who is the ideal candidate to Radium-223 treatment?



Obrigado pela atenção

[thiago.oncologia@gmail.com](mailto:thiago.oncologia@gmail.com)